

A Systematic study of the brain base arteries in broad-snouted caiman (*Caiman latirostris*)

Almeida, L.^{1*} and Campos, R.^{1,2}

¹Post-Graduation Program in Veterinary Sciences, School of Veterinary Medicine, Federal University of Rio Grande do Sul – UFRGS, 9090, Bento Gonçalves Avenue, CEP 91540-000, Porto Alegre, RS, Brazil

²Morphological Science Department, Basic Health Science Center, Federal University of Rio Grande do Sul – UFRGS, 9090, Bento Gonçalves Avenue, CEP 91540-000, Porto Alegre, RS, Brazil

*E-mail: l.almeida@terra.com.br

Abstract

The objective of this study was to describe and systematize the encephalic arterial vascularization of this reptile, by providing a standard irrigation model with its major variations. Thirty broad-snouted caiman heads and two whole specimens were used. The arterial system was filled with red-colored latex. Only a single source of blood supply was observed in caimans and it originated from the left aortic arch. This vessel is called the azygos carotid artery. At the caudal base of the skull, ventral to the first cervical vertebrae, it divided into two internal carotid arteries. The internal carotid arteries divided into a rostral branch and a short caudal branch at the hypophysis level, which continued naturally as the caudal cerebral artery. The short caudal branch gave off its medium-caliber portion which, gave off the mesencephalic and the ventral rostral cerebellar arteries. Then this caudal branch anastomosed with its contralateral counterpart, forming the basilar artery. This artery followed the ventral median fissure of the medulla oblongata, giving off the ventral caudal cerebellar and dorsal spinal arteries, and abandoning the cranial cavity through the foramen magnum as the ventral spinal artery. The rostral branch gave off the middle cerebral, rostral cerebral and rostral communicating arteries. The middle cerebral artery arose from a network originated from one to five collateral branches of the rostral branch of the internal carotid artery. It was observed that the cerebral arterial circle was rostrally and caudally closed and, therefore, the cerebral blood supply was exclusively made by the carotid system.

Keywords: cerebral arteries, brain vascularization, reptiles, caiman latirostris, alligator.

1 Introduction

Due to farm production of broad-snouted caimans, a species belonging to the Brazilian fauna, and to IBAMA's (Brazilian Institute of Environment and Natural Renewable Resources) authorization to commercialize their valued skin and meat, there is increased interest in caiman production for national and international markets. Information available on the cerebral blood supply of this reptile is rare. Literature consulted yielded only a few descriptions about the embryonic development of the brain circulation of three alligators and the cerebrovascular alterations that occur after birth (BURDA, 1969). In addition, there were some descriptions about the cerebral vascularization in turtles (KAPPERS, 1933; SCHEPERS, 1939; BURDA, 1965; FRIZZO, CAMPOS, SEVERINO et al., 1994) and the intracranial arterial system of *Crotaphytus collaris* (lizard) (BURDA, 1966) and *Sphenodon punctatus* (DENDY, 1909). This study aims to systematize the brain base arteries of the broad-snouted caiman, describing a standard model of irrigation and the main variations, in this species. These informations contribute for the studies in this area of the comparative anatomy about the phylogenetic development of the blood supply to the central nervous system.

2 Material and methods

Thirty *Caiman latirostris* (*C. latirostris*) heads with neck all males, along with two whole specimens (male and female) from Criatório Mister Cayman, under the authorization of the Brazilian Institute of Environment and Renewable Natural Resources (IBAMA) were used. The animals were approximately three years old, weighing 8 to 10 kg. The animals were sacrificed according to routine slaughterhouse norms. The thirty heads were sectioned at the third cervical vertebra level. The azygos carotid artery was cannulated before its division into right and left internal carotid arteries. The arterial system was washed with cold (15 °C) 0.9% saline solution (100 mL/animal) mixed with 2500 IU heparin (Heparin; Cristália Produtos Químicos Farmacêuticos Ltda, Itapira, SP, Brazil). Drainage was through the jugular veins. Subsequently, the system was filled with latex injection (Cola 603, Bertoncini Ltda, São Paulo, SP, Brazil) coloured with red pigment (Suvinil Corante – BASF S.A., São Bernardo do Campo, SP, Brazil), at a volume of 10 mL/animal. The samples remained for at least one hour under running water for latex polymerization. A window was made in the cranial vault. The samples were fixed by submersion in 20% formaldehyde for seven days. The encephalon with a spinal cord segment was removed. Subsequently, the dura mater

was also removed and the arteries were dissected. The two whole specimens were submerged in formaldehyde 20%. Seven days later, the thoraco-abdominal cavity was opened through a ventral median line incision extending cranially to the ventral part to the body of the mandible, for observation a source of blood supply to the brain.

The brains with their vessels were analyzed using magnifying glasses (LTS illuminated magnifier with a 5x magnification, Stemi SV8 Zeiss, Goettingen, Germany). To record the results, schematic drawings of the arteries of the 30 brains with the ventral view of the brain, were produced. The relative vessel caliber was described and compared in relationship to the caliber of the internal carotid artery. When practical, vessels were named according to *Nomina Anatomica Avium* (1993), since caimans are reptiles whose morphology is likely more similar to birds than mammals with regard to the *Nomina Anatomica Veterinaria* (INTERNATIONAL..., 2005). Additionally, some designations were given according to the interpretation of authors' previous studies. For further documentation, some samples were photographed. The occurrence and distribution of the vessels were expressed as a percentage of a thirty brain samples examined.

3 Results

The azygos carotid artery arose from the left aortic arch (*Arcus aortae sinister*) in the two whole specimens. It projected craniomedially towards the ventral median line of the neck, dorsal to the esophagus until it reached the caudal base of the skull, ventral to the first cervical vertebrae. Here the artery, divided into right and left internal carotid arteries (*Arteria carotis interna*) in all 30 samples, at an approximate divergence angle of 70°.

The internal carotids entered their respective carotid foramina, located lateral to the single occipital condyle and foramen magnum. The internal carotid artery ran cranially through the carotid canal (*Canalis caroticus*) until it reached the sella turcica, where it arose lateral to the hypophysis, to pierce the dura mater (*Dura mater encephali*). Just before approaching the hypophysis, still inside the canal, an intercarotid anastomosis occurred (Figure 1). After the intercarotid anastomosis, the internal carotid artery continued in all samples as, a large caliber artery, the internal ophthalmic artery (Figure 1), which turned rostroventrally exiting the cranial cavity via its foramen, lateral to the optic foramen, into the orbit. A medium caliber vessel, the rostral branch, was dispatched after curving dorsally alongside the tuber cinereum. Then, the internal carotid artery continued as a short large caliber caudal branch (Figures 2 and 3), which continued naturally as the caudal cerebral artery, after caudally emitting the medium caliber caudal branch.

The rostral branch of the internal carotid artery, which is a medium-caliber vessel, projected rostrolaterally, crossing ventral to the optic tract towards the cerebral hemisphere base. At the optic nerve, curved medially, passing over the nerve terminating as the rostral cerebral artery (Figures 2 and 3). During its rostral course, the rostral branch gave off one to five collateral branches, which formed the middle cerebral artery network. The right and left rostral branches of the internal carotid artery were single in 86.7% and double in 13.3% of cases (Figure 4).

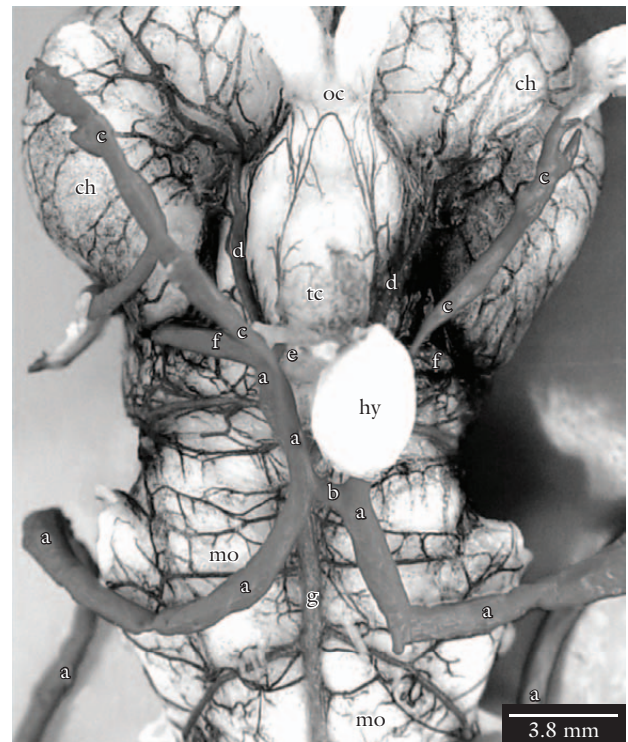

Figure 1. Detail of the ventral view of the caiman brain, showing the arrival of the internal carotid arteries that were removed from the carotid canal. a, internal carotid artery; b, intercarotid anastomosis; c, internal ophthalmic artery; d, rostral branch of a; e, caudal branch of a; f, caudal cerebral artery; g, basilar artery; oc, optic chiasm; tc, tuber cinereum; ch, cerebral hemisphere; hy, hypophysis; mo, medulla oblongata. Bar = 3.8 mm.

The middle cerebral artery did not occur as an individualized vessel but was network of vessels originating from the one to five collateral branches of the rostral branch of the internal carotid artery (Table 1). The middle cerebral artery network projected laterally on the ventral surface of the cerebral hemisphere forming successive anastomoses, whose main branches were distributed on the largest ventrolateral part of the ventral surface of the cerebral hemisphere (Figures 2 and 3). Its terminal branches anastomosed in “*osculum*” with the convex hemispherical collateral branches of the interhemispheric artery, at the beginning of the convex surface of the cerebral hemisphere, whereas the rostral branches of the middle cerebral artery network anastomosed like a large-caliber vessel and the anastomosis caliber of the caudal branches was at the capillary level. Caudally, at the cerebral hemisphere base, in the region that would correspond to the piriform lobe, the terminal branches of the middle cerebral artery anastomosed with the terminal branches of the I (first) central branch of the caudal cerebral artery.

The rostral cerebral artery, a small-caliber vessel, projected rostro-medially from the rostral branch, continuing from the last collateral component that formed the middle cerebral artery network, after crossing the optic nerve, passed between the optic chiasm and the ventral surface of the cerebral hemisphere. Here the terminal end of the rostral cerebral artery anastomosed “*in osculum*” with its contralateral

counterpart, forming the rostral communicating artery (Figure 3), dorsal to the optic chiasm effectively completing the cerebral arterial circle (*Circulus arteriosus cerebri*). It appeared as a single vessel in 90.0%, and as a double vessel in 10.0% of the cases. The rostral cerebral artery gave off branches (Table 2), as did the rostral communicating artery.

These branches continued rostrally, bordering and shortly after penetrating the cerebral longitudinal fissure (*Fissura longitudinalis cerebri*).

The internal carotid artery, after giving off its rostral branch, continued dorsally for a few millimeters as its caudal large-caliber branch. The caudal cerebral artery was

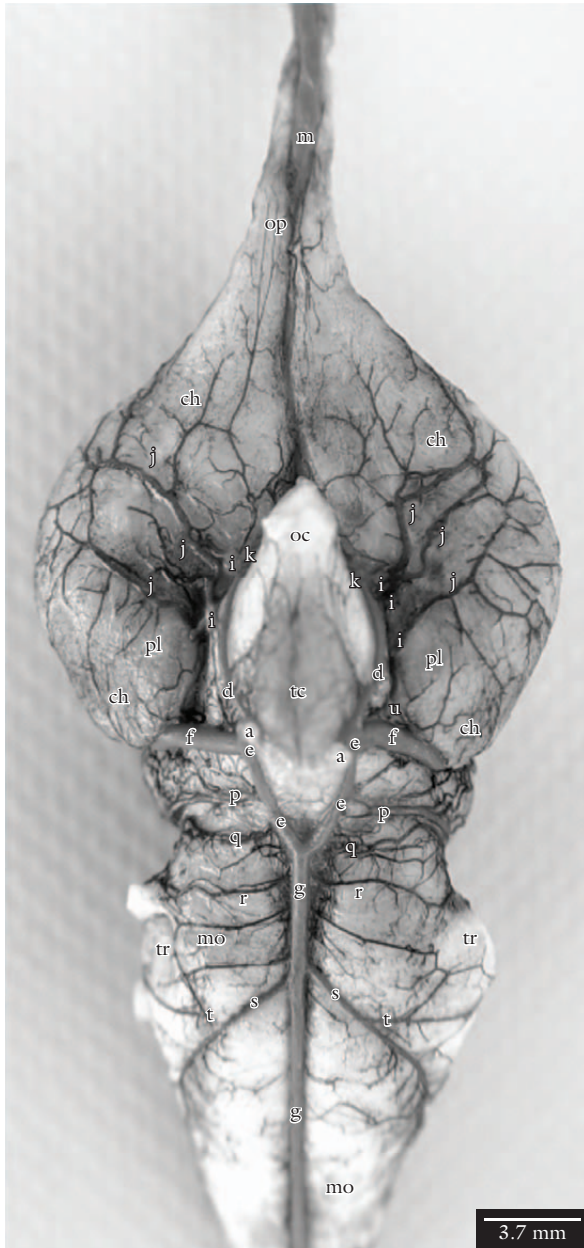


Figure 2. Ventral view of the arteries at the base of the brain. a, internal carotid artery; d, rostral branch of a; e, caudal branch of a; f, caudal cerebral artery; g, basilar artery; i, branches that form the middle cerebral artery; j, middle cerebral artery network; k, rostral cerebral artery; m, common ethmoidal artery; n, ethmoidal artery; o, medial artery of the olfactory bulb; p, mesencephalic artery; q, ventral rostral cerebellar artery; r, ventral caudal cerebellar artery; s, dorsal spinal artery; t, trigeminal artery; u, I central branch of f; op, olfactory peduncles; ch, cerebral hemisphere; oc, optic chiasm; tc, tuber cinereum; pl, piriform lobe; mo, medulla oblongata; tr, trigeminal nerve. Bar = 3.7 mm.

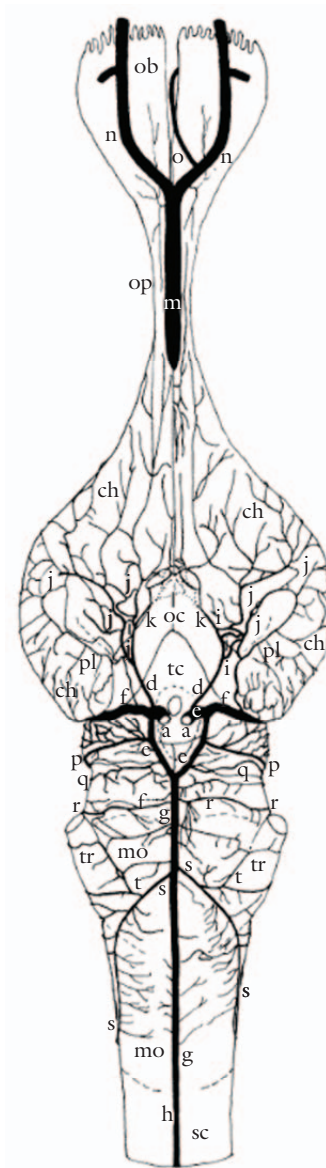


Figure 3. Schematic drawing showing the standard distribution of the arteries at the base of the caiman brain in a ventral view. a, internal carotid artery; d, rostral branch of a; e, caudal branch of a; f, caudal cerebral artery; g, basilar artery; h, ventral spinal artery; i, branches that form the middle cerebral artery; j, middle cerebral artery network; k, rostral cerebral artery; l, rostral communicating artery; m, common ethmoidal artery; n, ethmoidal artery; o, medial artery of the olfactory bulb; p, mesencephalic artery; q, ventral rostral cerebellar artery; r, ventral caudal cerebellar artery; s, dorsal spinal artery; t, trigeminal artery; u, I central branch of f; ob, olfactory bulb; op, olfactory peduncles; ch, cerebral hemisphere; oc, optic chiasm; tc, tuber cinereum; pl, piriform lobe; mo, medulla oblongata; tr, trigeminal nerve; sc, spinal cord.

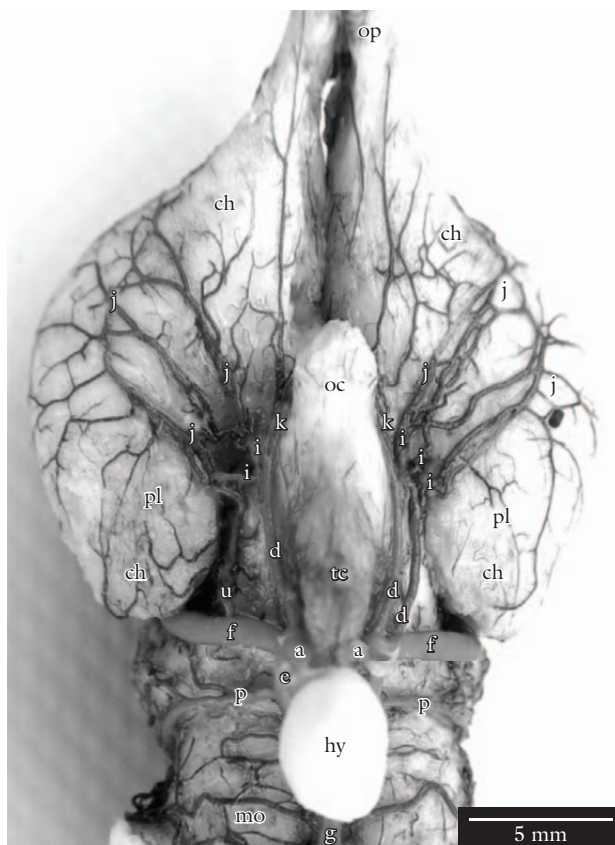


Figure 4. Detail of the ventral view of the caiman brain, showing the duplicity of the rostral branch of the internal carotid artery. a, internal carotid artery; d, rostral branch of a; e, caudal branch of a; f, caudal cerebral artery; g, basilar artery; i, branches that form the middle cerebral artery; j, middle cerebral artery network; k, rostral cerebral artery; p, mesencephalic artery; u, I central branch of f; op, olfactory peduncles; ch, cerebral hemisphere; pl, piriform lobe; oc, optic chiasm; tc, tuber cinereum; hy, hypophysis; mo, medulla oblongata. Bar = 5 mm.

the natural continuation of the caudal large-caliber branch, immediately after this latter gave off, caudally, a collateral medium-caliber vessel in an unusual way (Figures 2 and 3). The medium-caliber portion projected caudalwards giving off laterally collateral branches, namely the mesencephalic artery and ventral rostral cerebellar artery. The caudal branch curved medially, anastomosing with its contralateral counterpart forming the basilar artery, thus closing the arterial circle caudally (Figures 2 and 3).

The caudal cerebral artery was a large-caliber vessel, which projected laterodorsally and at the optic tract, gave off I (the first) central branch to the piriform lobe. Then, it penetrated into the cerebral transverse fissure (*Fissura transversa cerebri*), sequentially giving off the following vessels: diencephalic artery, a II (second) central branch, occipital hemispheric branches, pineal artery to pineal gland and other parietal organs (paraphyses, dorsal sac) and, furthermore, to the choroid plexus of the third and lateral ventricles. The caudal cerebral artery then abandoned the cerebral transverse fissure, projecting rostrally and sagittal to the cerebral longitudinal fissure as the interhemispheric artery, which issued convex hemispheric branches. Once

Table 1. Number of branches that formed the middle cerebral artery.

Number of branches	RMCA (%) average range ($\bar{x} \pm s$)	LMCA (%) average range ($\bar{x} \pm s$)
1	3.3 \pm 3.3	10.0 \pm 5.5
2	63.3 \pm 8.8	53.3 \pm 9.1
3	23.4 \pm 7.7	26.7 \pm 8.1
4	6.7 \pm 4.5	6.7 \pm 4.5
5	3.3 \pm 3.3	3.3 \pm 3.3

RMCA – Right Middle Cerebral Artery; LMCA – Left Middle Cerebral Artery.

Table 2. Collateral branches of the rostral cerebral artery.

Collateral branches	RRCA (%) average range ($\bar{x} \pm s$)	LRCA (%) average range ($\bar{x} \pm s$)
0	6.7 \pm 4.5	-
1	43.3 \pm 9.0	36.7 \pm 8.8
2	43.3 \pm 9.0	56.6 \pm 9.0
3	6.7 \pm 4.5	6.7 \pm 4.5

RRCA – Right Rostral Cerebral Artery; LRCA – Left Rostral Cerebral Artery.

the interhemispheric arteries reached the caudal third of the olfactory peduncles, they anastomosed forming a common ethmoidal artery, which projected rostroventrally, penetrating the cerebral longitudinal fissure. At the medium third of the olfactory peduncles, it emerged ventrorostrally, dividing into the right and left ethmoidal arteries, which progressed into the nasal cavities, vascularizing them. Only one ethmoidal artery issued to both antimeres a medial artery of the olfactory bulb (Figure 3).

The mesencephalic artery, the main collateral branch of the medium-caliber portion belonging to the caudal branch of the internal carotid artery (Figure 2 and 3), was present as a single vessel in both antimeres, and projected laterodorsally under the optic tract, vascularizing it. At the caudal border of the optic lobe, it issued the dorsal rostral cerebellar artery into the fissure between the cerebellum and optic lobes. From there, it continued as the dorsal caudal cerebellar artery along the dorsal surface of the cerebellum. Next to the caudal border of the same, it showed an anastomosis with its contralateral counterpart, caudally heading, side by side, towards the obturator membrane and choroid plexus of the fourth ventricle. When the calibers of the mesencephalic arteries were compared, there was equivalence in 73.3% of the cases between the two antimeres. On the other hand, it presented a larger caliber to the right in 20.0% and to the left in 6.7% of the cases.

The ventral rostral cerebellar artery was originated from the converging medium-caliber portion of the caudal branch of the internal carotid artery (Figures 2 and 3). It projected latero-dorsally, surrounding the mesencephalic body until it reached the flocculus of the cerebellum, anastomosing and forming an arterial network with branches of the mesencephalic artery and the ventral caudal cerebellar artery, vascularizing that latter. The right ventral rostral cerebellar artery occurred as a single vessel in 86.7% and as a double

vessel in 13.3% of the specimens. On the other hand, the left ventral rostral cerebellar artery was single in 80.0%, double in 16.7%, and absent in 3.3% of the specimens.

The basilar artery was formed from an anastomosis between two converging medium-caliber portions of the caudal branch of the internal carotid artery. This anastomosis closed the cerebral arterial circle caudally. The basilar artery went caudally to the tuber cinereum, following the ventral median fissure (*Fissura mediana ventralis*) of the medulla oblongata, until it abandoned the cranial cavity through the foramen magnum as the ventral spinal artery. The basilar artery gave off its most important collateral branches, the ventral caudal cerebellar and dorsal spinal arteries (Figures 2 and 3). Its course was straight in 76.6% and slightly sinuous in 23.3% of the samples. Some millimeters from its formation, the basilar artery gave off its collateral branch, the caudal ventral cerebellar artery. In the right antimeres, this vessel was single in 96.7% and double in 3.3% of the cases, while in the left antimeres, the vessel was single in 93.3% and double in 6.7% of the specimens. It should be pointed out that, in cases of duplicity, the caudal component had a larger caliber in both antimeres.

The dorsal spinal artery, the main collateral branch of the basilar artery, was always a single medium-caliber vessel in both antimeres, issued at the level of the apparent origin of the V pair of cranial nerve (trigeminal nerve). It projected latero-caudally until it reached the dorsal surface of the spinal cord, at the foramen magnum level, continuing laterally in this surface. In 50.0% of the samples, the right dorsal spinal artery was originated a few millimeters more caudally than its left counterpart, whereas this origin was more rostral in 46.7% and symmetric for both in 3.3% of the samples.

The trigeminal artery, the first collateral branch of the dorsal spinal artery, projected latero-rostrally from this latter, forming anastomoses with the ventral caudal cerebellar artery, accompanying the trigeminal nerve (Figures 2 and 3). The right trigeminal artery was a single vessel in 90.0% of the specimens, which was directly issued from the dorsal spinal artery. On the other hand, it showed duplicity in 10.0% of the samples, being the first component of larger caliber originated from the basilar artery, before this latter issued the right dorsal spinal artery. The left trigeminal artery, in turn, was a single vessel in 86.7% and double in 13.3% of the specimens, being the first vessel originated from the basilar artery and the second one directly issued from the left dorsal spinal artery.

The cerebral arterial circle of the broad-snouted caiman was rostrally and caudally closed in all samples and the cerebral blood supply was exclusively made by the internal carotid arteries, i.e., the carotid system (Figures 2 and 3). The rostral closure occurred through an anastomosis among the last ramifications of the rostral branches, at the level of the optic chiasm, through the rostral communicating artery, which acted as the connection of the rostral cerebral arteries. The caudal closure occurred at a few millimeters caudal to the tuber cinereum, at the basilar artery formation.

4 Discussion

With regard to the cerebral blood supply in caimans, no reference on the subject was found in all literature consulted, as authors would usually start their description based on a

carotid artery already at the base of the skull. In caiman, only a single vessel supplied both the right and left carotids and it originated from the left aortic arch. This vessel was named the azygos carotid artery, because this species did not show a typical common carotid artery. The ventral part of the neck and also the mandible were vascularized by branches from the subclavian arteries.

In caimans, the internal carotid artery passed through the carotid canal inside the base of the skull and, at the caudal limit of the hypophyseal fossa, it curved dorsally and penetrated into the cranial cavity. These results coincide with those observed in iguanas (DENDY, 1909); turtles (BURDA, 1965); lizards (BURDA, 1966); reptiles (GILLILAN, 1967) and in three alligators (BURDA, 1969). Before abandoning the carotid canal, the two internal carotid arteries anastomosed caudal to the hypophysis, forming an intercarotid anastomosis (BURDA, 1965, 1969). On the other hand, this anastomosis of the internal carotid arteries was not observed in *Crotaphytus collaris* (BURDA, 1966).

The first branch of the internal carotid artery after the anastomosis was a large branch which exited the cranial cavity rostroventrally, to the orbit via a special foramen located laterally to the optic foramen. This artery was named the internal ophthalmic artery in turtles (KAPPERS, 1933; SCHEPERS, 1939). This is similar to large orbital artery described by Burda (1965, 1969) in turtles and alligators, which arose from the cranial cavity through a same special foramen in the rostral limit of the hypophyseal fossa (sella turcica).

In *Cayman latirostris*, the internal carotid artery divided into a rostral and caudal branch at the base of the tuber cinereum, similar to the description of Gillilan (1967) in lizards, turtles and alligators (DE VRIESE, 1905; DENDY, 1909; KAPPERS, 1933; SCHEPERS, 1939). In turtles of the genus *Pseudemys*, Burda (1965) described that the internal carotid artery, after the orbital artery's origin, continued rostrally as the cerebral carotid artery, dividing into the rostral encephalic artery (rostral branch) and caudal encephalic artery (caudal branch) (BURDA, 1966, 1969). On the other hand, in a research about the blood supply of the subfornical organ of 32 *Chysemys dobignii* turtles, Frizzo, Campos, Severino et al., (1994) described that the internal carotid artery formed three divisions: terminal, rostral and caudal.

According to De Vriese (1905), the rostral and caudal branch of the cerebral carotid artery in turtles presented identical calibers, whereas in saurians and crocodylians, the caliber of the rostral branch was larger than its caudal counterpart. However, Gillilan (1967) reported that the caliber of the caudal branch of the internal carotid artery in reptiles was slightly larger than the rostral branch. According to the reports made by Gillilan (1967), the caudal branch was more developed than the rostral one in caimans, in addition to having two portions of large and medium calibers.

In caimans, the middle cerebral artery did not occur as individualized vessel as it normally does in other animal species but was a network of vessels originating from the one to five collateral branches of the rostral branch of the internal carotid artery. This latter then, continuing rostrally as the rostral cerebral artery's terminal branch. In alligators, according to Burda (1969), the rostral branch was rostrally projected, originating a large middle cerebral artery, and

this latter then issued several secondary branches towards the lateral surface of the cerebral hemisphere (SCHEPERS, 1939), continuing as the rostral cerebral artery around the rostral border of the optic chiasm (DE VRIESE, 1905). In *Sphenodon*, Dendy (1909) observed that the rostral portion (rostral branch) of the internal carotid artery gave off the caudal, middle and rostral arteries (KAPPERS, 1933; SCHEPERS, 1939; BURDA, 1966; GILLILAN 1967). In turtles, Burda (1965) reported that the rostral branch of the internal carotid artery gave off one lateral choroidal artery, one ophthalmic artery and one middle cerebral artery, ending as the rostral cerebral artery. It should be pointed out that some cases of duplicity in the rostral branch of the internal carotid artery were observed in caimans, a fact that was not mentioned by any other author.

Similarly to the findings in *Cayman latirostris*, Gillilan (1967) observed in reptiles that the middle cerebral artery was either originated as a single trunk, which was quickly subdivided into several arteries, or was formed from many short trunks, which were branched and distributed through the piriform cortex, on the ventro-lateral surface of the cerebral hemisphere and paleopallium area, continuing dorso-laterally towards the convex surface of the cerebral hemisphere. In *Sphenodon*, Dendy (1909) described that the behavior and distribution of the middle cerebral artery were similar to those described by Burda (1969) in alligators; however, the artery continued rostro-medially to the olfactory tract as the olfactory artery (BURDA, 1965, 1966).

In caimans, the terminal end of the rostral cerebral artery anastomosed to form the rostral communicating artery. However, the rostral communicating artery was double in 10.0% of the cases, and this observation has not been described by other authors in any reptile. Regarding the rostral cerebral artery, Dendy (1909), in *Sphenodon*, described that the rostral branch after emitting the middle cerebral artery, continued rostro-medially inside the cerebral longitudinal fissure. Additionally, a connection between the rostral cerebral arteries was not observed and, consequently, the cerebral arterial circle remained rostrally open (DE VRIESE, 1905; SCHEPERS, 1939). According to Burda (1969), the rostral cerebral artery in alligators was originated after the emission of the middle cerebral artery; however, a medial branch (terminal branch) was given off to the longitudinal fissure of the brain, which anastomosed with its contralateral counterpart, forming the rostral communicating artery and thus closing the cerebral artery circle rostrally.

In caimans, the medium-caliber portion of the caudal branch projected caudally, giving off its collateral branches laterally, namely the mesencephalic artery and the rostral ventral cerebellar artery. In turtles, Burda (1965) described that the caudal branch continued caudally, giving off the following arteries as its collateral branches: caudal cerebral, mesencephalic and cerebellar. Moreover, Burda (1965) described that the caudal branches curved medially and anastomosed, caudally to the origin of the cerebellar arteries, thus forming a basilar artery. In alligators, according to Burda (1969), the caudal branch only gave off the mesencephalic artery and, immediately after that, it also anastomosed to form the basilar artery (DE VRIESE, 1905). Similarly, in caimans, it was observed that the caudal branch curved medially, anastomosing with its contralateral counterpart and originating the basilar artery.

In turtles, according to Schepers (1939), the caudal branch of the internal carotid artery gave off the following arteries as its collateral branches: diencephalic, mesencephalic, cerebellar and choroid plexus of fourth ventricle, which continued medio-caudally, bordering the ventral median line of the medulla oblongata, without the formation of the basilar artery; however, in some cases, anastomotic bridges were observed between the caudal branches. In turtles, Burda (1965) observed the presence of anastomotic bridges between the caudal branches. From that point, the structure was denominated basilar artery, which remained double along the medulla oblongata. In caimans, the basilar artery was formed from an anastomosis between two converging medium-caliber portions of the caudal branch of the internal carotid artery. This fusion closed the cerebral arterial circle caudally, and it occurred in the ventral median line, at a few millimeters caudally to the tuber cinereum. In reptiles, Gillilan (1967) reported that the caudal branch gave off the caudal tectal artery and cerebellar artery, whose branches continued dorsally towards the optic lobes and cerebellum, respectively. He further stated that the caudal branches then followed caudally, curving medially to form the basilar artery, thus closing the cerebral arterial circle, caudally (DENDY, 1909; BURDA, 1966; FRIZZO, CAMPOS, SEVERINO et al., 1994). In caimans, the basilar artery was a single vessel, which went along the ventral median line of the medulla oblongata, until it abandoned the cranial cavity through the foramen magnum as the ventral spinal artery (BURDA, 1969).

In caimans, the caudal cerebral artery was the natural continuation of the large-caliber portion of the caudal branch of the internal carotid artery. This latter projected latero-dorsally and it curved caudo-dorsally inside the cerebral transverse fissure following the pineal peduncle, and then emerging in the occipital pole of the cerebral hemisphere. From that point, it projected rostrally and sagittally to the cerebral longitudinal fissure as the interhemispheric artery. In turtles, according to Schepers (1939), the dorsal branch of the internal carotid artery issued the caudal cerebral artery at the level of the optic tract. This latter then continued latero-dorsally towards the caudal pole of the cerebral hemispheres (DENDY, 1909; BURDA, 1966; KAPPERS, 1933). According to Burda (1969), in his study about alligators at several embryonic stages, the caudal cerebral artery showed discrepancies that were hard to explain with regard to its origin. In embryos, the caudal cerebral artery was issued from the caudal branch of the cerebral carotid artery; however, in adults, it was originated at the angle formed between the caudal and rostral branches. Furthermore, he stated that the caudal cerebral artery in adult alligators was originated from the rostral branch, continuing dorsally and then penetrating into the fissure between the two cerebral hemispheres and the optic lobes, giving off several branches to the caudolateral and caudo-medial regions of the hemisphere and to the rostral surface of the optic lobe, and also one branch to the choroid plexus of the third ventricle. It curved caudo-dorsally, emerging at the occipital pole of the cerebral hemisphere, projecting rostrally along the dorsal surface of the hemisphere. Additionally, in caimans, the right and left caudal cerebral arteries followed a dorsal path as parallel interhemispheric arteries and, next to the rostral limit of the hemispheres, these two vessels anastomosed forming

the common ethmoidal artery, which continued between the olfactory peduncles rostrally towards the cranial cavity (BURDA, 1969).

In caiman, the ethmoidal artery of one single antimer gave off the medial artery of the olfactory bulb, which vascularized both olfactory bulbs. However, in alligators, Burda (1969) described that it was the common ethmoidal artery which originated a small medial olfactory artery between the olfactory bulbs, bifurcating into the right and left ethmoidal arteries (GILLILAN, 1967). The large caliber of the caudal cerebral artery and its terminal branches should be noted, in addition to the fact that the internal ethmoidal arteries in caimans are different from all other reptiles because they are responsible for the vascularization of the entire nasal cavity.

According to the descriptions made by Burda (1965), in which the mesencephalic artery in turtles was the main collateral branch of the caudal branch of the internal carotid artery, which in turn vascularized the optic lobe and cerebellum (SCHEPERS, 1939), the same feature was observed in caimans. In *Crotaphytus collaris*, Burda (1966) observed that the mesencephalic artery originated from the rostral branch and then continued caudo-dorsally towards the convex surface of the optic lobe. It was divided into many vessels, of which some branches reached the cerebellum. Burda (1969), furthermore, described that the caudal branch curved caudally in alligators, giving off the mesencephalic artery. In *Sphenodon*, Dendy (1909) stated that the mesencephalic artery, denominated bigeminal artery, showed the same distribution described by Burda (1966) in lizards.

In caimans, the basilar artery presented a slight sinuosity in a few specimens. It gave off the ventral caudal cerebellar artery and the dorsal spinal artery as its collateral branches. In *Crotaphytus collaris*, according to Burda (1966), the basilar artery presented a sinuous path along the ventral surface of the medulla oblongata, which then gave off small branches to the medulla and a prominent vessel, namely the internal auditory artery, which continued dorso-medially towards the choroid plexus of the fourth ventricle. Then, at the caudal limit of the medulla oblongata, the basilar artery continued caudally as the ventral spinal artery. In reptiles, according to Gillilan (1967), the basilar artery gave off several branches latero-dorsally towards the encephalic trunk and a pair of prominent vessels, namely the dorsal medullar artery (dorsal spinal artery), which continued towards the dorsal surface of the spinal cord. On the other hand, Burda (1969) stated that, in alligators, the basilar artery presented a sinuous path in the ventral median line of the medulla oblongata, giving off the lateral medullar artery (dorsal spinal artery) latero-dorsally, which in turn gave off a small-caliber trigeminal branch to the dorsal surface of the trigeminal nerve.

5 Conclusion

The main differences of the brain vascularization observed in caimans were: a network-type formation of the middle cerebral artery; a highly developed basilar artery, as well as

its continuation, namely the ventral spinal artery; and the blood supply to the nasal cavity made by the caudal cerebral artery. In the literature consulted, no authors observed this latter finding in any other animal species, either in lower or higher vertebrates. In caimans, the cerebral arterial circle was rostrally closed by the rostral communicating artery and caudally closed by the formation of the basilar artery, similarly as described by Burda (1969) in alligators (DE VRIESE, 1909; GILLILAN, 1967).

Acknowledgements: This research received financial support from the Programa Institucional de Capacitação de Docentes e Técnicos-PICDT of Universidade Federal do Paraná and from the Brazilian Foundation (CAPES).

References

- BAUMEL JJ., KING, AS., BREAZILE, JE., LUCAS, AM. and EVANS, HE. *Handbook of avian anatomy*. Nomina anatomica avium. 2nd ed. Cambridge: Nuttall Ornithological Club, 1993.
- BURDA, D. Development of intracranial arterial patterns in turtles. *Journal of Morphology*, 1965, vol. 116, p. 171-188.
- BURDA, D. Developmental aspect of intracranial arterial supply in the alligatorbrain. *Journal of Comparative Neurology*, 1969, vol. 135, p. 369-380.
- BURDA, D. Embryonic modifications of lacertilian. Intracranial arteries. *American Journal of Anatomy*, 1966, vol. 11, p. 743-754.
- DE VRIESE, B. Sur la signification morphologique des artères cérébrales. *Archives de Biologie*, 1905, vol. 21, p. 357-457.
- DENDY, A. The intracranial vascular system of *Sphenodon*. *Philosophical Transactions of the Royal Society of London, Biological Sciences*. 1909, vol. 200, B, p. 403-426.
- FRIZZO, MES., CAMPOS, R., SEVERINO, AG. and ACHAVAL, M. The vasculature of the subfornical organ of the turtle *Chrysemys dorsibigni*. *Italian Journal of Anatomy and Embryology*, 1994, vol. 99, no. 2, p. 109-121.
- GILLILAN, L. A comparative study of the extrinsic and intrinsic arterial bloodsupply to brains of the submammalian vertebrates. *American Journal of Anatomy*. 1967, vol. 130, p. 175-196.
- International Committee on Veterinary Gross Anatomical Nomenclature. *Nomina Anatomica Veterinaria*. 5th ed. New York, 2005. 198 p.
- KAPPERS, CUA. The forebrain arteries of plagiostomes, reptiles, birds, and monotremes. *Proceedings of the Royal Academy of Amsterdam*, 1933, vol. 36, p. 52-62.
- SCHEPERS, GWH. The blood vascular system of the brain of *Testudo geometrica*. *Journal of Anatomy*, 1939, vol. 73, p. 451-495.

Received September 10, 2010

Accepted February 23, 2011