

## Anatomic study of the portions long and oblique of the vastus lateralis and vastus medialis muscles: review article

Vieira, EPL.\*

Departamento de Educação Física, Universidade Salgado de Oliveira – UNIVERSO, São Gonçalo, RJ, Brazil

\*E-mail: elcianavieira@yahoo.com.br

### Abstract

Although not mentioned directly in the classical anatomical literature, the vastus lateralis and vastus medialis, which make up the quadriceps femoris muscle, show variations in their anatomical structures due to the presence of long and oblique portions receiving the designation of vastus lateralis longus, vastus lateralis oblique to the vastus lateralis and vastus medialis oblique and vastus long, for the vastus medialis. The aim of this paper is to review the scientific literature regarding the presence of long and oblique portions of the broad medial and lateral portions recognize these as integral parts, anatomically, the quadriceps femoris. To this end, we used published articles in magazines and journals, located through Medline, and Lilacs Excerpta Medica, and the Portal Capes, with the key words: quadriceps, vastus medialis, vastus lateralis, vastus medialis longus, vastus medialis oblique, vastus lateralis longus and vastus lateralis oblique. Used to, still, a master's thesis, located at Portal Capes, plus textbooks and atlases of anatomy. Among the 27 surveyed, only two do not recognize these portions as independent structures, considering the differences in fiber orientation. Of the 18 studied anatomy books, no mention such parts. However, eight anatomy books describe differences in trajectory of fiber insertions of the vastus lateralis and vastus medialis. Before this study it was concluded that these portions have not only morphological differences but also in other respects proved through scientific studies being published in some of them considered independent muscle suggesting inclusion of muscles in Anatomical Nomina.

**Keywords:** quadriceps, vastus medialis oblique, vastus long, vastus lateralis oblique, vastus lateralis longus.

### 1 Introduction

The human body contains over 600 skeletal muscles account for approximately 40% of body weight in most adults (VAN DE GRAAFF, 2003), responsible for a fundamental characteristic of human behavior, intentional movement (SMITH, WEISS and LEHMKUHL, 1997) by muscle contraction (GOSS, 1988; VAN DE GRAAFF, 2003; SMITH, WEISS and LEHMKUHL, 1997).

The complex of the quadriceps has recently been the object of interest because of their histological composition and the anterolateral part that is often the target of electromyographic studies and biopsies (MAHON, TOMAN, WILLAN et al., 1984; GOLLAND, WILLIAM and MAHON, 1986). Although most authors in anatomical ignore the possibility of morphological variation in gross muscular architecture, these differences contribute to widespread changes in histomorphometric data confirmed by muscle biopsy samples (WILLIAM, MAHON and GOLLAND, 1990).

The quadriceps is composed structurally of four distinct muscles: the rectus femoris, vastus lateralis, vastus medialis and vastus intermedius (BASMAJIAN, 1971; BOUCHET and CUILLET, 1984; CHIARUGI, 1958; SNELL, 1984; HAMILTON, 1982; HOLLINSHEAD and ROSS, 1991; LOCKART, HAMILTON and FYFE, 1959). Its name is derived from Latin, hip + caput, or thigh muscle with four heads (MOORE and DALLEY, 2001). He composes the main part of the anterior muscles of the thigh, being

a powerful extensor of the leg, considering the largest and most powerful muscle in the human body (Moore and Dalley, 2001; DI DIO, 2002) capable of generating more than 450 or 4450 N.kg<sup>-1</sup> of inner strength (SMITH, WEISS and LEHMKUHL, 1997) being cited as the muscle more "beautiful" with its four body parts differing from each other (LAST, 1952).

The heads of four major knee extensor are innervated by the femoral nerve (PUTZ and PABST, 2000; TESTUT and JACOB, 1932; WARWICK and WILLIAM, 1973) and its branches (THIRANAGAMA, 1990).

Although Duchene (1949) has called the quadriceps femoris and triceps considered inconvenient to separate the vastus medialis and vastus lateralis as two distinct and inseparable in their physiological action, constituting a single muscle could be called biceps femoris extensor, several studies showed that the quadriceps muscle varies in its morphology.

However, although not listed in the Handbook of Anatomical Nomenclature published by the Brazilian Society of Anatomy (SOCIEDADE..., 2001) and the classical anatomical studies (BASMAJIAN, 1971; BOUCHET and CUILLET, 1984; CHIARUGI, 1958; HAMILTON, 1982; LOCKART, HAMILTON and FYFE, 1959; TESTUT and LATARGET, 1988), lateral and oblique portions referring to the large medial and lateral have been studied by several authors.

## 2 Anatomical description

### 2.1 *Vastus lateralis muscle and portions*

According to the classical anatomic literature, the origin of the vastus lateralis is on the greater trochanter, lateral lip of linea aspera femoris and the lateral intermuscular septum and its insertion at the base patellar ligament using the patella and tibial tuberosity (SNELL, 1984; TESTUT and LATARGET, 1988; WARWICK and WILLIAM, 1973; CHIARUGI, 1958; HAMILTON, 1982).

The vastus lateralis is considered the largest part of the quadriceps femoris (GOSS, 1988; LAST, 1952; WARWICK and WILLIAM, 1973) to form thick, wide (GARDNER, GRAY and O'RAILLY, 1988; ROMANES, 1972) and fusiform appearance (CHIARUGI, 1958) is intimately attached to the vastus intermedius in its middle third, (ROMANES, 1972; WARWICK and WILLIAM, 1973).

A detailed description about the insertion of the vastus lateralis varies according to some authors. According to Warnick and William, in your insertion point there is a strong aponeurosis inferiorly on the inner surface, and it condenses into a flat tendon that inserts on the lateral patellar edge merging with the quadriceps tendon (WARWICK and WILLIAM, 1973). Hamilton (1982) refers to the insertion of this muscle through aponeurotic strip ahead of the tibial condyles. Testud and Jacob (1932) describe as issues that form the patella tendon, addressing oblique and inferior in relation to the axis of the leg, finishing segments: the first would medial fibers forming a common tendon, the second is a strong aponeurotic lamina resistant and located behind the rectus femoris tendon inserting along with this muscle at the base and the third patellar segment fibers are more lateral and ending at the upper edge of the patella.

The first reference about the possible differences in morphology of the vastus lateralis, performed by Last (1952), reported that not all fibers originated from the femur, such as classical literature claimed, because a considerable muscle of the lower portion of this muscle stemmed directly from lateral intermuscular septum. Later, another study went on to describe the fibers of that muscle as not only attached to the quadriceps tendon, but also to the lateral border of the patella extending down joining the lateral joint capsule to reinforce it (MERCHANT and MERCER, 1974).

The first citation of the scientific division of the vastus lateralis in two heads: a long head inserted on the base of the kneecap, called the vastus lateralis longus and other short inserted into the medial patellar margin, called the vastus lateralis oblique, occurred through a survey of the dissection of 42 cadavers, to ascertain whether there were significant differences in the angles of attachment between men and women discussing the importance of the vastus lateralis for a surgical technique called "lateral release" (HALLISEY, DOHERTY, BENNET et al., 1987; SCHARF, WEINSTABL, FIRBA, 1986). Other scholars have continued to earlier research and confirmed the presence of an additional portion of the vastus lateralis, but none of these researchers described the detailed anatomy of these parts. Another study of 40 cadavers showed that one third of these individuals had an additional head associated with the wide side, calling the group quinticeps femoral extensor (LIEB

and PERRY, 1968; SOUZA and GROSS, 1991; WILLIAM, MAHON and GOLLAND, 1990).

Recently, the vastus lateralis muscle has to be studied anatomically presenting the two parts: long and oblique (BEVILÁQUA-GROSSI, 1996; BEVILÁQUA-GROSSI, MONTEIRO-PEDRO, SOUSA et al., 2004).

The oblique portion arises from the linea aspera of the femur and lateral intermuscular septum (BEVILÁQUA-GROSSI, MONTEIRO-PEDRO and BÉZINI, 2004; BASMAJIAN, 1971; BOUCHET and CUILLET, 1984; ROMANES, 1972; HOLLINSHEAD and ROSS, 1991; SNELL, 1984), a more fibrous expansion of the iliotibial tract (TESTUT and JACOB, 1932), by inserting the tendon itself, which is directed inferior and lateral to the vastus lateralis muscle over this by joining the superolateral border of the patella tendon to form a single, often attached to the joint capsule, as shown in Figure 1 (BEVILÁQUA-GROSSI, 1996; BEVILÁQUA-GROSSI, MONTEIRO-PEDRO and BÉZINI, 2004).

The distal fibers of the vastus lateralis oblique were presented in interdigitated lateral retinaculum, which is formed from the expansions of tendinous insertions of the vastus lateralis muscle, inserted in the tibia and patella which, in turn, reinforces the anterolateral region of knee, as shown in Figure 3 (LOCKART, HAMILTON and FYFE, 1959; MERCHANT and MERCER, 1974) and iliotibial tract (BEVILÁQUA-GROSSI, MONTEIRO-PEDRO and BÉZINI, 2004; CARNEIRO FILHO, LAREDO FILHO, NAVARRO et al., 1986). Morphologically, the vastus lateralis oblique is divided into: a distal surface and a spiral proximal portion with deep longitudinal fibers in the femoral shaft below the belly of the vastus lateralis muscle along, mingling with the vastus intermedius, second Figure 2 (BEVILÁQUA-GROSSI, 1996; BEVILÁQUA-GROSSI, MONTEIRO-PEDRO and BÉZINI, 2004). Some authors recognize the clinical importance of the vastus lateralis obliquus in patellar stability and the maintenance of balance patellofemoral along with the vastus medialis oblique considering those portions in both the vastus lateralis and the vastus medialis, as independent muscles, contributing to patellar alignment suggesting the inclusion of the words: oblique vastus lateralis and vastus medialis oblique in Nomina Anatomica (WEINSTABL, FIRBA and SCHARF, 1989).

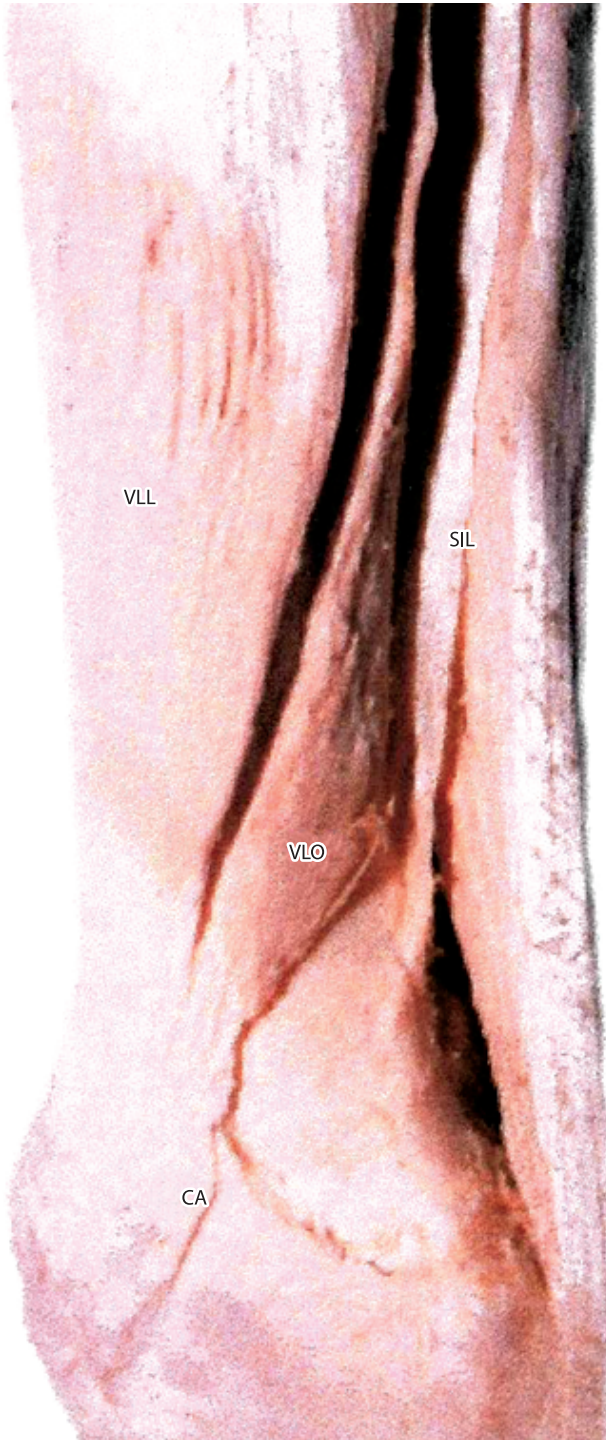
The vastus lateralis longus has its origin in the femoral trochanter and lateral lip of linea aspera of the femur, as found in the anatomical literature (BASMAJIAN, 1971; BOUCHET and CUILLET, 1984; CHIARUGI, 1958; DI DIO, 2002; HAMILTON, 1982; SNELL, 1984; PUTZ and PABST, 2000; TESTUT and LATARGET, 1988), showing extensive superficial aponeurosis in more than two thirds of the proximal surface and a deep aponeurosis in the distal 1/3 separating it from the vastus lateralis obliquus (BEVILÁQUA-GROSSI, MONTEIRO-PEDRO and BÉZINI, 2004). Its insertion is on the superolateral border of the patella by the patellar ligament by means of union with the tendon of vastus lateralis oblique, forming a single tendon (TESTUT and JACOB, 1932; TESTUT and LATARGET, 1988).

A study with the aim of analyzing the angles of insertion in the vastus lateralis longus and vastus lateralis obliquus (SCHARF, and WEINSTABL, ORTHNER, 1985), values were the vastus lateralis for long between 10 and 17 and

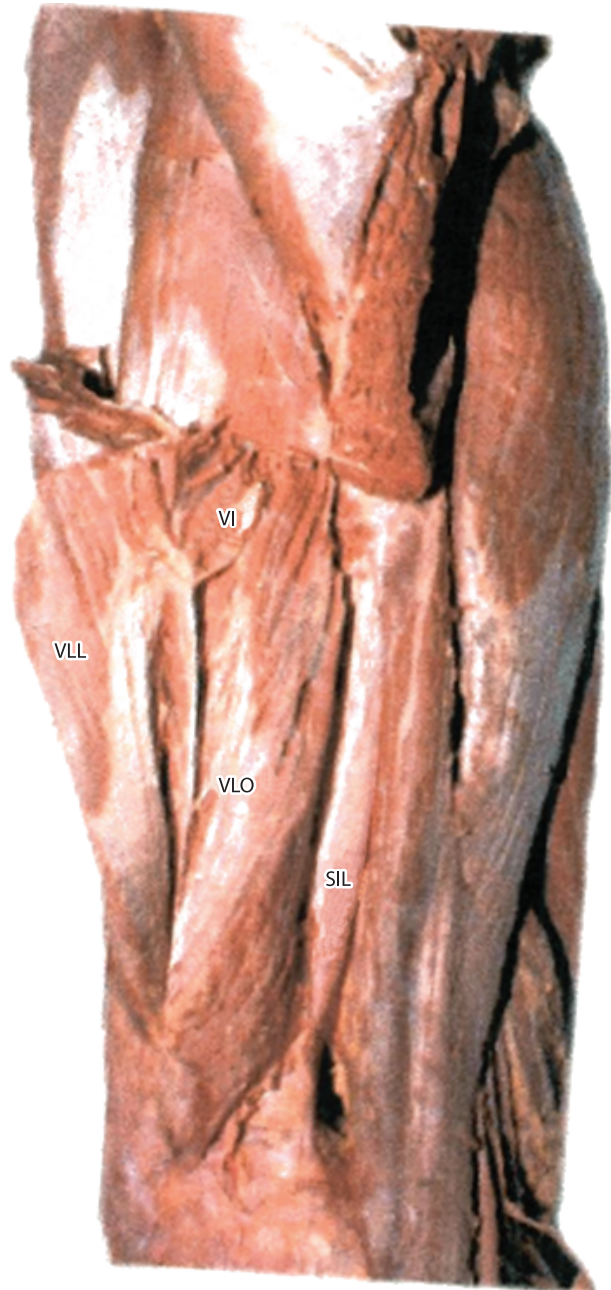to the wide side oblique between 26 and 41 highlighting the importance of analyzing the angles of insertion of the quadriceps to the understanding of patellar stability and possible extension movement disorders (HUGNSTON, WALSH and PUDDY, 1984).

## 2.2 *Vastus medialis and portions*

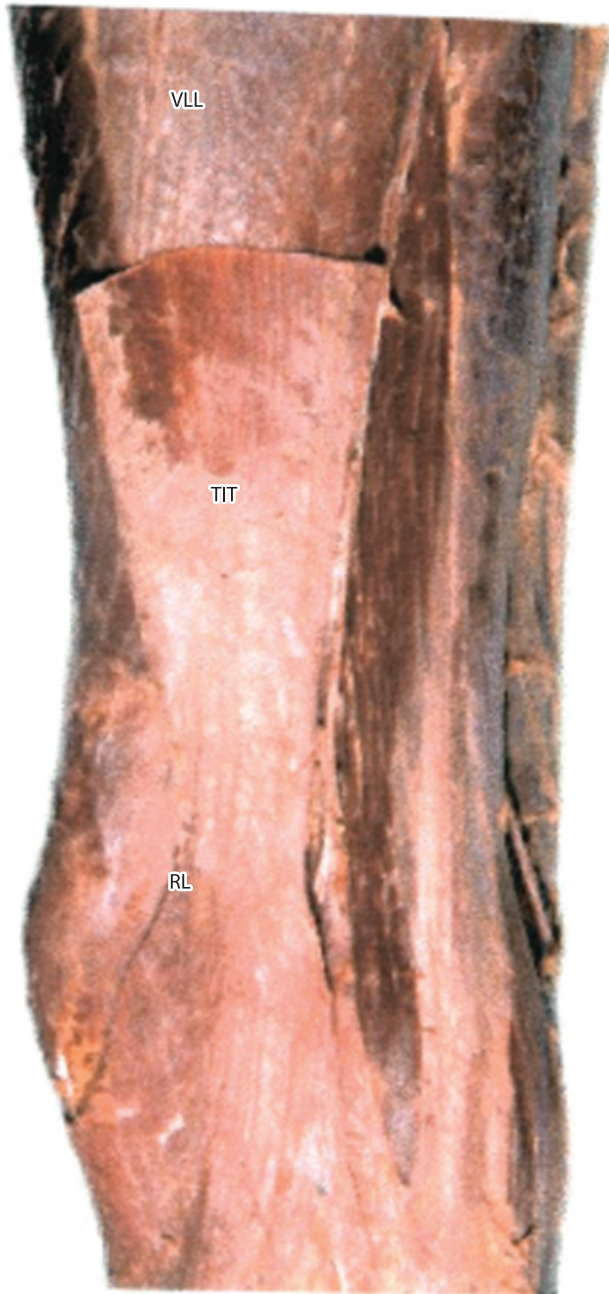
The vastus medialis has its origin in the medial lip of linea aspera and its insertion in the proximal and lateral margin of the patella, tibial tuberosity and proximal tibial (BASMAJIAN, 1971; BOUCHET and CUILLET, 1984; CHIARUGI, 1958; DI DIO, 2002; HAMILTON, 1982; SNELL, 1984; PUTZ and PABST, 2000; TESTUT and LATARGET, 1988).



**Figure 1.** Origin and insertion of the vastus lateralis oblique. Origin of the vastus lateralis oblique lateral intermuscular septum (LIS). Insertion of the vastus lateralis obliquus (VLO), toward the inferior and lateral to the vastus lateralis longus (VLL), joining it in a common tendon at the superolateral edge of the kneecap, often attached to the capsule (CA).




**Figure 2.** Lateral oblique vastus mingling with the vastus intermedius. Vastus lateralis longus (VLL) sectioned to show the proximal portion of the vastus lateralis obliquus (VLO) with its longitudinal fibers in the femoral diaphysis, mingling with the vastus intermedius muscle (VI).



**Figure 3.** Extensive lateral oblique clouded by the iliotibial tract. Iliotibial tract (ITT), giving rise to the lateral retinaculum (LR), and completely covering the vastus lateralis oblique (VLO).

The division of the vastus in two parts, one long and one oblique, was introduced by Lieb and Perry (1968), in accordance with Figure 4. It is known that portions of this muscle differ anatomical (BOSE, KANAGASUNTHERAM and OSMAN, 1980; HUBBARD SAMPSON and ELLEDGE, 1997; LIEB and PERRY, 1968; WEINSTABL, FIRBA and SCHARF, 1989), functional (BOSE, KANAGASUNTHERAM and OSMAN, 1980; GOODFELLOW, HUNGENFORD and ZENDEL, 1976; HUBBARD SAMPSON and



**Figure 4.** Vastus medialis and its long and oblique portions. a) Dissection of the vastus medialis showing the frontal plane defined by Lieb and Perry (1968): A-anterior, D-distal, fp-frontal plane, Po-posterior, Pr-proximal, medial vml-wide long-vmo vastus medialis oblique. b) Dissection of the vastus medialis showing the frontal plane. A-anterior, D-distal, Po-posterior, Pr-proximal, vm-medialis vastus.

ELLEDGE, 1997; HUGNSTON, WALSH and PUDDY, 1984; LIEBE, NEVADA and PERRY, 1971; RUFFIN and KININGHAM, 1993), immunohistochemical (TRAUNIK, PERNUS and ERZEN, 1995) and also in the pattern of innervation (LIEB and PERRY, 1968; SCHARF, WEINSTABL and FIRBA, 1986; THIRANAGAMA, 1990). However, despite the recognition of the difference in orientation of the proximal and distal fibers of this muscle, some authors do not consider those portions as separate anatomical structures (HUBBARD, SAMPSON and ELLEDGE, 1997). However, some studies consider the long and vast vastus medialis oblique functionally different (BOSE, KANAGASUNTHERAM and OSMAN, 1980; LIEB and PERRY, 1968; SPEAKMAN and WEISBERG, 1977). A study reveals the trajectory of the muscle fibers of the vastus medialis split into 3 parts: the first would be 1/3 of the top is composed of parallel fibers that arise vertically from the intertrochanteric line, converging toward the top edge of a muscle aponeurosis found deeply, the second would be 1/3 middle part which is composed of parallel fibers obliquely, running about 15-35° to the longitudinal axis of the femur, arising from the lip of the linea aspera femoris

and the medial intermuscular septum inserting the medial margin and the anterior surface of the aponeurosis found and, finally, the third, which would be the bottom 1/3 of the muscle was composed of parallel fibers being in mostly aligned more obliquely to 40-55° to the longitudinal axis of the femur presenting appearance almost horizontal, arising mainly from the adductor magnus tendon and partially on the medial intermuscular septum (GÜNAL, ARAÇ, SAHINOGLU et al., 1992; LIEB and PERRY, 1968; SCHARF, WEINSTABL and ORTHNER, 1985).

The vastus is along the proximal portion of the vastus medialis and inserts into the base of the patella, with the fibers deviating from an average of 15 to 18° medially from the longitudinal axis of the femur (SMITH, WEISS and LEHMKUHL, 1997; TRAUNIK, PERNUS and ERZEN, 1995). This muscle contributes directly to the knee extension (HUBBARD, SAMPSON and ELLEDGE, 1997; TRAUNIK, PERNUS and ERZEN, 1995).

The vastus medialis oblique is the distal part having its origin mainly in the adductor magnus tendon and its insertion into the medial margin of the patella (BOSE, KANAGASUNTHERAM and OSMAN, 1980; TRAUNIK, PERNUS and ERZEN, 1995), and its fibers are more horizontal, shifting on an average of 50 to 55 medial femoral shaft (TRAUNIK, PERNUS and ERZEN, 1995; SMITH, WEISS and LEHMKUHL, 1997). Its action is mainly related to the last phases of knee extension (BOSE, KANAGASUNTHERAM and OSMAN, 1980; GOH, LEE and BOSE, 1995; LIEB and PERRY, 1968), however the function of preventing a lateral subluxation of the patella (THIRANAGAMA, 1990), acting on the medial patellar stabilization during knee extension (HUBBARD, SAMPSON and ELLEDGE, 1997; SOUZA and GROSS, 1991; TRAUNIK, PERNUS and ERZEN, 1995) by maintaining the alignment of the patella to slip on the femoral condyles, directing his forces medially thereby neutralize the forces directed laterally by the vastus lateralis (TRAUNIK, PERNUS and ERZEN, 1995; SMITH, WEISS and LEHMKUHL, 1997). In clinical orthopedics and realibitação, the vastus medialis oblique is considered a separate part of the vastus medialis is an acceptable solution to problems involving the rehabilitation of the stabilization of the patella (HUBBARD, SAMPSON and ELLEDGE, 1997).

Lieb and Perry (1968) describe the innervation of the vastus medialis as independent for the vastus medialis oblique. In another study dissections involving the vastus in humans, the researchers relied on a separation plan along a branch of the femoral nerve as a basis for dividing the muscle into two anatomical heads: the vastus medialis oblique long and wide (GÜNAL, ARAÇ, SAHINOGLU et al., 1992; LIEB and PERRY, 1968; SCHARF, WEINSTABL and ORTHNER, 1985). Some observations were made reporting a double nerve supply, both from the femoral nerve (BASMAJIAN, 1971; LIEBE, NEVADA and PERRY, 1971; THIRANAGAMA, 1990). But, Günal, Araç, Sahinoglu et al. (1992), reported an additional innervation to the vastus medialis oblique through the saphenous nerve.

In an analysis of the patellar insertion angles of the different components of the quadriceps were found 65° for the vastus medialis oblique and 50° for the vastus long (HUGNSTON, WALSH and PUDDY, 1984). Despite this fact, in another analysis of the angle of insertion of portions of the same

muscle, were found the following values: 15 to 18° to the vastus long and 46 to 52° to the vastus medialis oblique (SCHARF, WEINSTABL and FIRBA, 1986; WEINSTABL, FIRBA and SCHARF, 1989).

### 3 Materials and methods

Contributors to this anatomical review, articles published in magazines and journals, located through Medline, and Lilacs Excerpta Medica, and the Portal Capes, with the key words: quadriceps, vastus medialis longus, vastus medialis oblique, vastus lateralis longus and vastus lateralis oblique. We used also a master's thesis, located at Portal Capes (BEVILAQUA-GROSSI, 1996), as well as textbooks and atlases of anatomy, published in Brazil (DI DIO, 2002; GARDNER, GRAY and O'RAILLY, 1988; GOSS, 1988; HAMILTON, 1982; HOLLINSHEAD and ROSS, 1991; MOORE and DALLEY, 2001; SMITH, WEISS and LEHMKUHL, 1997; SNELL, 1984; PUTZ and PABST, 2000; VAN DE GRAAFF, 2003), England (LOCKART, HAMILTON and FYFE, 1959; WARWICK and WILLIAM, 1973; ROMANES, 1972), Argentina (BOUCHET and CUILLET, 1984), Spain (TESTUT and LATARGET, 1988; TESTUT and JACOB, 1932), United States (BASMAJIAN, 1971) and Italy (CHIARUGI, 1958).

### 4 Results

For the realization of this study were surveyed 27 scientific articles and a master's thesis, and only two among these articles do not consider such portions as independent structures, while acknowledging the difference in fiber orientation. The others acknowledge the presence of such portions as well as their morphological, functional, the pattern of innervation and histochemistry, considering such portions as independent structures. The inclusion of these portions to their proper classifications in Nomina Anatomica is suggested by only one scientific paper.

We studied anatomy books, including classic and contemporary, refers directly to any long and oblique portions of the quadriceps femoris. However, eight classical anatomy books describe the differences in the direction of the fibers, especially the insertion of the vastus medialis and vastus lateralis.

### 5 Conclusion

Although the literature does not recognize the anatomical parts morphology of the vastus lateralis and vastus medialis, studies show the presence of portions of these long and oblique muscles that make up the quadriceps. They have different origin and insertion, although some authors do not consider as independent structures anatomically (HUBBARD, SAMPSON and ELLEDGE, 1997) and functionally (DUCHENNE, 1949). Portions act reported, mainly in maintaining patellar stability during movement of knee extension (HUBBARD, SAMPSON and ELLEDGE, 1997; HUGNSTON, WALSH and PUDDY, 1984; SMITH, WEISS and LEHMKUHL, 1997; TRAUNIK, PERNUS and ERZEN, 1995; WEINSTABL, FIRBA and SCHARF, 1989), however, present opposing orientations and are involved in the imbalance between these muscles can cause an excessive displacement during

movement of the patellofemoral joint (OLIVEIRA, VASCONCELOS, LEOCÁDIO et al., 2007).

Thus, these parts show not only morphological differences, as also in the patterns of functional innervation and histochemistry, demonstrated by published scientific studies and in some of them considered independent muscles getting the names of the vastus medialis oblique, vastus long oblique vastus lateralis, vastus lateralis longus (OLIVEIRA, VASCONCELOS, LEOCÁDIO et al., 2007) counting, yet, at the suggestion of his inclusion in the Nomina Anatomica (WEINSTABL, FIRBA and SCHARF, 1989).

## References

- BASMAJIAN, JV. *Grant's - Method of Anatomy*. 8th ed. Baltimore: Williams & Wilkins, 1971. p. 341-345.
- BEVILAQUA-GROSSI, D. *Músculo Vasto Lateral Oblíquo: Correlações Anátomo-Clinicas*. Piracicaba: Faculdade de Odontologia de Piracicaba, Universidade Estadual de Campinas, 1996. [Dissertação de Mestrado em Ciências].
- BEVILAQUA-GROSSI, D., MONTEIRO-PEDRO, V. and BÉRZINI, F. Análise funcional dos estabilizadores patelares. *Acta Ortopédica Brasileira*, 2004, vol. 12, n. 2, p. 99-104. <http://dx.doi.org/10.1590/S1413-78522004000200005>
- BEVILAQUA-GROSSI, D., MONTEIRO-PEDRO, V., SOUSA, CG., SILVA, Z. and BÉRZINI, F. Contribuição para o estudo anatômico da porção oblíqua do músculo vasto lateral. *Brazilian Journal of Morphological Sciences*, 2004, vol. 21, n. 1, p. 47-52.
- BOSE, K., KANAGASUNTERAM, R. and OSMAN, MBH. Vastus medialis oblique: an anatomical and physiologic study. *Orthopedics*, 1980, vol. 3, p. 880-883.
- BOUCHET, A. and CUILLET, J. *Anatomia Descriptiva, topográfica y funcional - Miembros inferiores*. 2th ed. Buenos Aires: Editora Médica Panamericana, 1984. p. 92-99.
- CARNEIRO FILHO, M., LAREDO FILHO, J., NAVARRO, RD. and MESTRINER, LA. Estudo anatômico da inserção do músculo "vastus lateralis" do músculo "quadriceps femoris" na patela. *A Folha Médica*, 1986, vol. 4, n. 93, p. 251-255.
- CHIARUGI, G. *Instituzione di anatomia dell'uomo*. 7th ed. Torino: Societa Editrice Libreria Milano, 1958. vol. 2, p. 202-230.
- DI DIO, AJL. *Tratado de Anatomia Sistemica Aplicada*. 2th ed. São Paulo: Atheneu Editora, 2002. vol. 1, p. 266-267.
- DUCHENNE, GB. *Physiology of motion*. Philadelphia: J.B.Lippincott Company, 1949. p. 275-302.
- GARDNER, E., GRAY, DJ. and O'RAILLY, R. *Anatomia: Estudo Regional do Corpo Humano*. 4th ed. Rio de Janeiro: Guanabara Koogan, 1988. p. 206-212.
- GOH, HCJ., LEE, CYP., BOSE, K. A Cadaver Of The Function Of The Oblique Part Of Vastus Medialis. *The Journal of Bone and Joint Surgery*, 1995, vol. 77-B, n. 2, p. 225-231.
- GOLLAND, JA., MAHON, M. and WILLIAN, PLT. Anatomical variations in human quadriceps femoris muscles. *Journal of Anatomy*, 1986, n. 146, p. 263-264.
- GOODFELLOW, JW., HUNGENFORD, DS. and ZENDEL, M. Patello femoral joint mechanics and pathology funcional anatomy of the patellofemoral joint. *Journal of Bone and Joint Surgery*, 1976, vol. 58B, n. 3.
- GOSS, MC. *Gray Anatomia*. 29th ed. Rio de Janeiro: Guanabara Koogan editora, 1988. p. 307-406.
- GÜNAL, I., ARAÇ, S., SAHINOGLU, R. and BIRVAR, K. The innervation of vastus medialis obliquus: Brief Reports. *The Journal of Bone and Joint Surgery*, p. 624, 1992.
- HALLISEY, MJ., DOHERTY, N., BENNET, WF. and FULKERSON, JP. Anatomy of the junction of the vastus lateralis tendon and patella. *Journal of Bone and Joint Surgery*, 1987, vol. 69A, n. 4, p. 545-549.
- HAMILTON, WJ. *Tratado de Anatomia Humana*. 2th ed. Rio de Janeiro: Interamericana, 1982. p. 151-162.
- HOLLINSHEAD, WH. and ROSSE, C. *Anatomia*. 4th ed. Rio de Janeiro: Interlivros edições, 1991. p. 314-322.
- HUBBARD, KJ., SAMPSON, WH. and ELLEDGE, RJ. Prevalence and morphology of the vastus medialis oblique muscle in human cadavers. *The Anatomical Record*, 1997, n. 249, p. 135-142.
- HUGNSTON, JC., WALSH, WM. and PUDDY, G. *Patellar subluxation and dislocation*. Philadelphia: W.B. Saunders Company, 1984. vol. 5, p. 1-41.
- LAST, RJ. On the form and structure of muscles. *Journal of Bone and Joint Surgery*, vol. 34B, p. 295-305, 1952.
- LIEB, FJ. and PERRY, J. Quadriceps function, an anatomic and mechanical study using amputated limbs. *Journal of Bone and Joint Surgery*, 1968, vol. 50A, p. 1535-1548.
- LIEBE, FJ., NEVADA, R. and PERRY, J. Quadriceps function: an electromyographic study under isometric conditions. *Journal of Bone and Joint Surgery*, 1971, vol. 53A, p. 749-758.
- LOCKART, RD., HAMILTON, GF. and FYFE, FW. *Anatomy of the human body*. Londres: Faber and Faber, 1959. p. 230-245.
- MAHON, M., TOMAN, A., WILLAN, PLT. and BABNALL, KM. Variability of histochemical and morphometric data from needle biopsy specimes of humam quadriceps femoris muscle. *Journal of the Neurological Sciences*, 1984, n. 63, p. 85-100. [http://dx.doi.org/10.1016/0022-510X\(84\)90111-4](http://dx.doi.org/10.1016/0022-510X(84)90111-4)
- MERCHANT, AC. and MERCER, R. Lateral release of the patella. *CORR - Clinical Orthopaedics and Related Research*, 1974, n. 103, p. 40-45.
- MOORE, LK. and DALLEY, FA. *Anatomia: orientada para clínica*. 4th ed. Rio de Janeiro: Guanabara Koogan editora, 2001. p. 471-472.
- OLIVEIRA, MI., VASCONCELOS, BE., LEOCÁDIO, PL., DUTRA FILHO, DA. and TEYMENY, AA. Atividade Eletromiográfica dos Músculos Vasto Medial e Vasto Lateral de Indivíduos Normais e com Disfunção Femoropatelar. *Revista da Saúde UCPEL*, 2007, n. 1, vol. 1, p. 91-96.
- ROMANES, GJ. *Textbook of Anatomy*. 17th ed. Londres: Oxford University Press, 1972. p. 369-371.
- RUFFIN, MT. and KININGHAM, RB. Anterior knee pain: the challenge of patellofemoral syndrome. *American Family Physician*, 1993, vol. 43, p. 185-194.
- SCHARF, W., WEINSTABL, R. and FIRBAS, W. Anastomische untrsuchungen am streckapparat des knieelenks und ihre klinische relevanz. *Unfallchirurg*, 1986, vol. 10, n. 89, p. 456-462.
- SCHARF, W., WEINSTABL, R. and ORTHNER, E. Anastomische untrsuchungen und klinische bedeutung zweir verchiedener anteile des musculus vastus medialis. *Acta Anatomica*, 1985, n. 123, p. 108-111. <http://dx.doi.org/10.1159/000146048>
- SMITH, KL., WEISS, LE. and LEHMKUHL, DL. *Cinesiologia Clínica de Brunnstrom*. 5th ed. São Paulo: Manole editora, 1997. p. 82-366.
- SNELL, RS. *Anatomia*. 2th ed. Rio de Janeiro: Medsi, 1984. p. 451-455.

- PUTZ, R. and PABST, R. *Atlas de Anatomia Humana*: Sobotta. 21th ed. Rio de Janeiro: Guanabara Koogan Editora, 2000. vol. 2, p. 314-315.
- Sociedade Brasileira de Anatomia - SBA. *Terminologia Anatômica*. Manole: São Paulo, 2001.
- SOUZA, DR. and GROSS, MT. Comparison of vastus medialis obliquus: vastus lateralis muscle integrated electromyographic ratios between healthy subjects and patients with patellofemoral pain. *Physical Therapy*, 1991, vol. 4, n. 71, p. 310-320.
- SPEAKMAN, HGB. and WEISBERG, J. The vastus medialis controversy. *Physiotherapy*, 1977, vol. 8, n. 63, p. 249-254.
- TESTUT, L. and LATARGET, A. *Tratado de Anatomia Humana*. 9th ed. Barcelona: Salvat, 1988. p. 1111-1134.
- TESTUT, L. and JACOB, O. *Tratado de Anatomia Topográfica com aplicações médico-cirúrgicas*. 5th ed. Barcelona: Salvat Editores, 1932. p. 982-1013.
- THIRANAGAMA, R. Nerve supply of the human vastus medialis muscle. *Journal of Anatomy*, 1990, n. 170, p. 193-198.
- TRAUNIK, L., PERNUS, F. and ERZEN, I. Histochemical and morphometric characteristics of the normal human vastus medialis longus and vastus medialis obliquus. *Journal of Anatomy*, 1995, n. 187, p. 403-411.
- VAN DE GRAAFF, MK. *Anatomia Humana*. 6th ed. São Paulo: Manole editora, 2003. p. 234-282.
- WARWICK, R. and WILLIAM, PL. *Gray's Anatomy*. 35th ed. Londres: Longman, 1973. p. 559-564.
- WEINSTABL, R., SCHARF, W. and FIRBAS, W. The extensor apparatus of the knee joint its peripheral vasti: anatomic investigation and clinical relevance. *Surgical and Radiologic Anatomy*, 1989, n. 11, p. 17-22. <http://dx.doi.org/10.1007/BF02102239>
- WILLIAN, TL., MAHON, M. and GOLLAND, AJ. Morphological variations of the human vastus lateralis muscle. *Journal of Anatomy*, 1990, n. 168, p. 235-239.

Received February 10, 2011  
Accepted September 8, 2011