

Incidence of the ossified pterygoalar ligament in Brazilian human skulls and its clinical implications

Rossi, AC.^{1*}, Freire, AR.¹, Manoel, C.¹, Prado, FB.¹,
Botacin, PR.² and Caria, PHF.¹

¹Department of Morphology, State University of Campinas – UNICAMP, Piracicaba, SP, Brazil

²Department of Basic Sciences, Paulista State University – UNESP, Araçatuba, SP, Brazil

*E-mail: anaclaudiarossi@fop.unicamp.br

Abstract

The ossified pterygoalar ligament is formed between the lateral lamina of the pterygoid process and the infratemporal surface of the sphenoid bone or its greater wing and was not connected to the sphenoid spine. The aim of this study was to evaluate the incidence of the ossified pterygoalar ligament in Brazilian human skulls and analyzing its clinical importance. 183 Brazilian adult (between 30 to 60 years old) dry human skulls were evaluated. Was evaluated the incidence of skulls with complete or partial ossification of the pterygoalar ligament, bilaterally and unilaterally and in the presence on the right and left sides. Were found 5 skulls had the ossified pterygoalar ligament, resulting in an overall incidence of 2.73%. There was 1 skull in the presence of the incomplete ossification of the pterygoalar ligament, unilaterally and on the left side resulting in incidence of 0.54%. There were 4 skulls in the presence of the complete ossification of the pterygoalar ligament, unilaterally and on the right side resulting in incidence of 2.18%. The ossified pterygoalar ligament is a major cause of the entrapment of the lingual nerve or a branch of the mandibular nerve and may cause mandibular neuralgia. The incidence of the ossified pterygoalar ligament and the pterygoalar foramen is low in the Brazilian population. However, these structures have clinical significance as this ligament establish relationships with the ovale foramen and difficulty in accessing in this foramen in a therapeutic approach.

Keywords: skull, incidence, ossification, pterygoalar ligament.

1 Introduction

The phenomenon of ossification in the region of skull has been described in several studies (LUDINGHAUSEN, KAGEYAMA, MIURA et al., 2006; DAS and PAUL, 2007). The ossification of the intrinsic ligaments of the sphenoid bone has been reported in the literature (SUAZO GALDAMES, ZAVANDO MATAMALA and SMITH, 2010).

The pterygospinous ligament extends from the pterygospinous process of the lateral lamina of the pterygoid process of the sphenoid bone, coursing inferior level of the oval foramen, to the spine of sphenoid bone in the infratemporal fossa (ERDOGMUS, PINAR and CELIK, 2009). In cases where the bony bridge was formed between the lateral lamina of the pterygoid process and the infratemporal surface of the sphenoid bone or its greater wing and was not connected to the sphenoid spine, it was decided to name these osseous structures “pterygoalar ligament” and “the pterygoalar foramen”, respectively (SKRZAT, WALOCHA and ŚRODEK, 2005). Occasionally the pterygospinal or the pterygoalar foramen also called crotaphitico-buccinatorium foramen (WILLIAMS, BANNISTER, BERRY et al., 2000).

These formations are related laterally with the oval foramen, from which the mandibular nerve emerges, and then enters in the infratemporal fossa (PEUKER, FISCHER and FILLER, 2001). Through of the foramen pterygoalar, pass some of the motor fibers of the trigeminal nerve (i.e. masseter and deep temporal nerves) (WILLIAMS, BANNISTER, BERRY et al., 2000). The lingual nerve

is a branch of the mandibular nerve, itself a branch of the trigeminal nerve (PEUKER, FISCHER and FILLER, 2001).

The pterygoalar ligament and foramen may be important in clinical practice, either by producing various neurological disturbances (SHAW, 1993), or by blocking the passage of a needle through the foramen ovale (PEUKER, FISCHER and FILLER, 2001).

The ossified pterygoalar ligament is a major cause of the entrapment of the lingual nerve or a branch of the mandibular nerve and may cause mandibular neuralgia (ERDOGMUS, PINAR and CELIK, 2009).

Therefore, the aim of this study was investigated the incidence of the pterygoalar bony bridges in Brazilian human skulls and discuss its clinical implications.

2 Material and methods

183 Brazilian adult (between 30 to 60 years old) dry human skulls belonging to the collection of the Laboratory of Anatomy of the Faculty of Dentistry of Araçatuba – UNESP and Piracicaba Dental School – UNICAMP. The skulls selected showed absent of abnormalities such as trauma or obvious morphological asymmetries.

Was evaluated the incidence of skulls with complete or partial ossification of the pterygoalar ligament, bilaterally and unilaterally and in the presence of the right and left sides. In the complete ossification of pterygoalar ligament there is a bony bridge between the superior segment of the posterior

edge of the lateral lamina of the pterygoid process and a process that emerges from the anterolateral area of the base of sphenoid spine. In this case, it is the pterygoalar foramen. In the incomplete ossification of pterygoalar ligament there is an elongation of a process in spina shape that originates from the anterolateral area of the sphenoid spine base, but that does not reach sufficiently elongation to contact with the lateral lamina of the pterygoid process.

The skulls were examined by one observer. The evaluation of incidence was performed three times by the same examiner at different times to avoid errors.

To obtain the results were evaluated the percentage (%) of the skulls with the presence of the ossified pterygoalar ligament.

3 Results

Of the 183 skulls examined in this study, 5 skulls had the ossified pterygoalar ligament, resulting in an overall incidence of 2.73%. There was 1 skull in the presence of the incomplete ossification of the pterygoalar ligament, unilaterally and on the left side resulting in incidence of 0.54% (Table 1). There were 4 skulls in the presence of the complete ossification of the pterygoalar ligament, unilaterally and on the right side resulting in incidence of 2.18% (Table 1).

4 Discussion

In this study, were observed complete (Figure 1) and incomplete ossified pterygoalar ligament (Figure 2). The incidence of these anatomical formations in the human population is a few known and there is only scarce information on its morphology in the literature (ERDOGMUS, PINAR and CELIK, 2009).

Patnaik, Rajan Singla and Bala (2001) discovered a pterygoalar ligament arising from the upper posterior border of the lateral pterygoid lamina and growing backwards and laterally towards the greater wing of sphenoid bone, similar to that demonstrated in this study (Figure 1). Many studies only evaluate the incidence of the pterygospinous ligament, Kapur, Dilberovic', Redzepagic' et al. (2000) obtained a lower prevalence of 1.31% of complete pterygospinous ligament ossification, from a sample of 305 Croats' skulls. Peker, Karakose, Anil et al. (2002) reported the presence of this bridge in 8.8% in skulls of an Anatolian population. Nayak, Saralaya, Prabhu et al. (2007) analyzed 416 Indian dried skulls; 9.61% of the samples presented the pterygospinous bony bridges, of which 5.76% was complete and 3.84% was incomplete.

Suazo Galdames, Zavando Matamala And Smith (2010) evaluated a sample of 312 skulls from a Brazilian population to complete and incomplete ossification of the pterygoalar ligament and obtained incidences of 3.84 and 22.43%, respectively. Unlike the present study which found incidences of 0.54 and 2.18%, respectively. Despite the difference, the incidences obtained in both studies in skulls of Brazilian population may be considered low. However, these osseous variations are important not only in anatomy, but also in clinical practice (ANTONOPOULOU, PIAGOU and ANAGNOSTOPOULOU, 2008).

These formations occupy a deep and high portion in the infratemporal fossa establishing important relationships with the mandibular nerve and its branches, the otic ganglion,

Table 1. The distribution of incomplete and complete pterygoalar ligament ossification considering the samples of 183 skulls.

	Incomplete ossification		Complete ossification	
	n	%	n	%
Bilateral	0	0.00	0	0.00
Unilateral	1	0.54	4	2.18
Right	0	0.00	4	2.18
Left	1	0.54	0	0.00

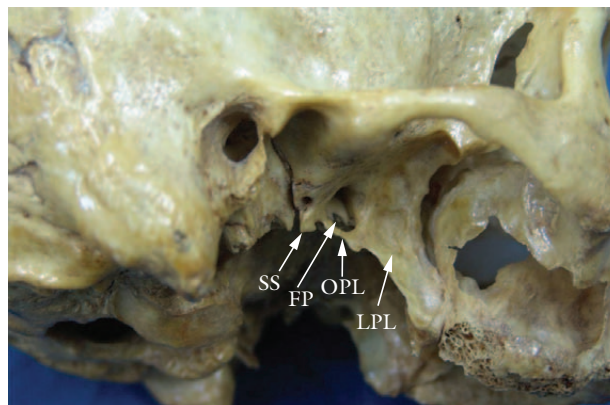


Figure 1. Region of the infratemporal fossa on the right side: SS – Sphenoid Spine; FP – Foramen Pterygoalar; OPL – Ossified Pterygoalar Ligament; LPL – Lateral Pterygoid Lamina.

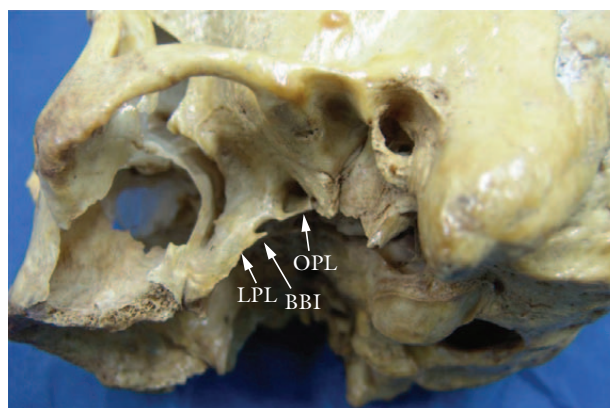


Figure 2. Region of the infratemporal fossa on the left side: LPL – Lateral Pterygoid Lamina; BBI – Bony Bridge Incomplete; OPL – Ossified Pterygoalar Ligament.

the median meningeal artery and vein, the tympanic nerve, the medial and lateral pterygoideus muscles. These are compressed against the bone formations and are capable of generating clinically important alterations (KRMPOTIC-NEMANIC, VINTER, HAT et al., 1999).

The incomplete or complete ossified pterygoalar ligament provides mandibular nerve compression. So, the entrapment of the mandibular nerve motor branches can lead to paresis or weakness in the innervated muscle. Compression of the sensory branches can provoke neuralgia or paraesthesia. Lingual nerve compression causes numbness, hypoesthesia

or even anaesthesia of the mucous of the tongue, anaesthesia and loss of taste in the anterior two-thirds of the tongue, anaesthesia of the lingual gums, as well as pain related to speech articulation disorders (PIAGKOU, DEMESTICHA, PIAGKOS et al., 2010).

The pterygoalar ligament can potentially press on the deep temporal, the lateral pterygoid and the buccal nerves (branches of the anterior trunk of the mandibular division of the trigeminal nerve), and on branches of the auriculotemporal nerve (KRMPOTIC-NEMANIC, VINTER, HAT et al., 1999). Such compression may cause chewing disorders, pain, numbness of the buccal region and changes to the parotid gland salivation (PEKER, KARAKOSE, ANIL et al., 2002).

Percutaneous procedures for the treatment of trigeminal neuralgia involve the penetration of the foramen ovale (KAPUR, DILBEROVIC', REDZEPAGIC' et al., 2000). This approach to the trigeminal ganglion may be difficult when the ossified pterygoalar ligament covers the foramen ovale. Thus, radiological guidance is required to visualize the foramen ovale and its related structures, which makes puncture easier and more precise (KAPUR, DILBEROVIC', REDZEPAGIC' et al., 2000). The pterygoalar bony bridge may act as a barrier to the passage of the needle through the foramen ovale, making it impossible to achieve successful transoval injections of anesthetics in trigeminal neuralgia (PIAGKOU, DEMESTICHA, PIAGKOS et al., 2010).

5 Conclusion

In conclusion, although the incidence of the ossified pterygoalar ligament and the pterygoalar foramen is low in the Brazilian population, it would seem important to extend knowledge of the morphology and topography of these structures. Thus, the presence of complete or incomplete ossification in the pterygoalar ligaments have clinical significance as these ligament establish relationships with the oval foramen and because of the effects that emerge from it, such as increasing difficulty in accessing the oval foramen in a therapeutic approach.

References

ANTONOPOULOU, M., PIAGOU, M. and ANAGNOSTOPOULOU, S. An anatomical study of the pterygospinous and pterygoalar bars and foramina - their clinical relevance. *Journal of Cranio-Maxillofacial Surgery*, 2008, vol. 36, no. 2, p. 104-8.

DAS, S. and PAUL, S. Ossified pterygospinous ligament and its clinical implications. *Bratislavské Lekárske Listy*, 2007, vol. 108, no. 3, p. 141-3.

ERDOGMUS, S., PINAR, Y. and CELIK, S. A cause of entrapment of the lingual nerve: ossified pterygospinous ligament - a case report. *Neuroanatomy*, 2009, vol. 8, p. 43-45.

KAPUR, E., DILBEROVIC', F., REDZEPAGIC', S. and BERHAMOVIC', E. Variation in the lateral plate of the pterygoid process and the lateral subzygomatic approach to the mandibular nerve. *Medicinski Arhiv*, 2000, vol. 54, no. 3, p. 133-7.

KRMPOTIC-NEMANIC, J., VINTER, I., HAT, J. and JALSOVEC, D. Mandibular neuralgia due to anatomical variations. *European Archives of Oto-Rhino-Laryngology*, 1999, vol. 256, no. 4, p. 205-8.

LUDINGHAUSEN, M., KAGEYAMA, I., MIURA, M. and ALKHATIB, M. Morphological peculiarities of the deep infratemporal fossa in advanced age. *Surgical and Radiologic Anatomy*, 2006, vol. 28, p. 284e292.

NAYAK, SR., SARALAYA, V., PRABHU, LV., PAI, MM. and VADGAONKAR, R. and D'COSTA, S. Pterygospinous bar and foramina in Indian skulls: incidence and phylogenetic significance. *Surgical and Radiologic Anatomy*, 2007, vol. 29, no. 1, p. 5-7.

PATNAIK, WG., RAJAN SINGLA, K. and BALA, S. Bilateral pterygo-alar bar and porus crotaphitico-buccinatorius e a case report. *Journal of the Anatomical Society of India*, 2001, vol. 50, p. 161-162.

PEKER, T., KARAKOSE, M., ANIL, A., TURGUT, HB. and GULEKON, N. The incidence of basal sphenoid bony bridges in dried crania and cadavers; their anthropological and clinical relevance. *European Journal of Morphology*, 2002, vol. 40, no. 3, p. 171-80.

PEUKER, ET., FISCHER, G. and FILLER, TJ. Entrapment of the lingual nerve due to an ossified pterygospinous ligament. *Clinical Anatomy*, 2001, vol. 14, no. 4, p. 282-4.

PIAGKOU, MN, DEMESTICHA, T., PIAGKOS, G., ANDROUTSOS, G. and SKANDALAKIS, P. Mandibular nerve entrapment in the infratemporal fossa. *Surgical and Radiologic Anatomy*, 2010, vol. 10.

SHAW, JP. Pterygospinous and pterygoalar foramina: a role in the etiology of trigeminal neuralgia? *Clinical Anatomy*, 1993, vol. 6, p. 173e178.

SKRZAT, J., WALOCHA, J., SRODEK, R. An anatomical study of the pterygoalar bar and the pterygoalar foramen. *Folia Morphologica*, 2005, vol. 64, p. 92-96.

SUAZO GALDAMES, I., ZAVANDO MATAMALA, D. and SMITH, RL. Anatomical Study of the Pterygospinous and Pterygoalar Bony Bridges and Foramina in Dried Crania and its Clinical Relevance. *International Journal of Morphology*, 2010, vol. 28, n. 2, p. 405-8.

WILLIAMS, PL., BANNISTER, LH., BERRY, MM., COLLIN, P., DYSON, M., DUSSEK, JE. and FERGUSON, MWJ. *Gray's anatomy*. 38th ed. New York: Churchill Livingstone, 2000. p. 588-801.

Received September 16, 2010

Accepted March 2, 2011