

## Accessory flexor carpi ulnaris muscle: a case report of a rare variation in human

Campos, D.\*, Nazer, MB., Bartholdy, LM. and Souza, PL.

Laboratory of Human Anatomy, Department of Biology and Pharmacy, University de Santa Cruz do Sul,  
Av. Independência 2293, CEP 96815-900, Santa Cruz do Sul, RS, Brazil

\*E-mail: dcampos@unisc.br

### Abstract

This study describes a rare case of the accessory muscle originated from the flexor carpi ulnaris muscle. An unusual variation of the flexor muscle was observed during the male cadaver dissection. The presence of an anatomical variation muscle was verified in the forearm on the left side of a 59 year old corpse settled in formol 10%. Morphological variability and clinical significance are reviewed.

**Keywords:** flexor carpi ulnaris muscle, accessory muscle, forearm, cadaver.

### 1 Introduction

The flexor carpi ulnaris muscle is the most medial of the muscles superficial flexors. It can make the flexing and adduction of the hand simultaneously. Her innervation is made completely by the ulnar nerve (MOORE and DALLEY, 2007).

According to Williams, Warwick, Dyson et al. (1995), it possesses heads umeral and ulnar united by an arch tendon, below these structures it travels the ulnar nerve and the posterior branch of the artery recurrent ulnar. The small head umeral originates from the medial epicondyle through a common tendon; the head ulnar is an extensive fixation of the medial margin of the olecranon and two thirds proximalis of the posterior border of the ulna through a common aponeurosis.

In this report, we described a rare anatomical variation involving this important muscle of the anterior area of the forearm and discuss the clinical implications of this anatomical variation.

### 2 Observations

During the regular dissection on the left side forearm in a 59-year-old White male cadaver, we detected that the flexor carpi ulnaris muscle presented an accessory muscle originated of her belly, third distal. The whole anterior area of the left side forearm was exposed with a dissection magnifying glass (ALLZWECK - LUPENLEUCHTE [1.75/2.25 magnification]). Muscle tendon, thickness and belly measurements were taken with the aid of a digital pachymeter (Digimess) (Figure 1). The flexor carpi ulnaris muscle presents a total length of 26.5 cm, with a muscular belly of 24.5 cm of length by 3.5 cm of width and 0.5 cm of thickness; starting from his third distal (see B<sub>1</sub>, Figure 1) there is the appearance of an accessory muscle presenting the following sizes: a total length of 14.5 cm, with a muscular belly of 12 cm of length by 2.5 cm of width and 0.5 cm of thickness. The accessory muscle is located between the flexor

carpi ulnaris muscle and the palmaris longus; his tendon with 2.5 cm of length and 0.3 cm of thickness crosses the retinaculum of the flexors ones in an own tunnel (see arrows, Figure 1). Medial to the nerve ulnar he penetrates in the abductor muscle of the minimum finger (see B<sub>2</sub>, Figure 1). There was no evidence of any pathological involvement of the accessory muscle and adjacent structures.

### 3 Discussion

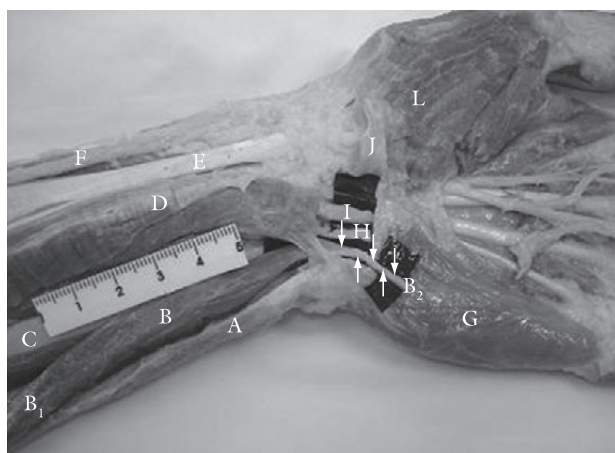
The importance of continuing to record and discuss anatomical anomalies was addressed recently by Hicks and Newell (1997) in the light of technical advances and interventional methods of diagnosis and treatment.

The ulnar tunnel is located at the proximal part of the hand radial to the pisiform bone and to the proximal part of the carpal tunnel. Inside it lies the ulnar nerve and artery. Compression of the ulnar nerve in this tunnel is often reported. Cysts, occupational trauma, fractures and muscle variations are among the main causes (KLEINERT and HAYES, 1971; SCHJELDERUP, 1964).

As mentioned by Khaledpour and Schindelmeyer (1994) the knowledge of such variations supplements the body of information on the muscles of the antebrachial and carpal regions may be important for hand surgeons. According to Soldado-Carrera, Vilar-Coromina and Rodriguez-Baeza (2000), accessory fasciculi of the hypothenar muscles have been involved in vascular and nerve compressions.

Olave, Del Sol, Gabrielli et al. (1997), comments that the flexor retinaculum lays dorsal to the contents of the ulnar tunnel and medially there were some anomalous muscle fibres extending between the pisiform bone and the retinaculum.

Natsis, Levva, Totlis et al. (2007), reports that after dissection of the left forearm of a 73-year-old female cadaver was found a reversed palmaris longus muscle. This means that the palmaris longus muscle was tendinous in its upper



**Figure 1.** Photograph of the left carpi ventral aspect demonstrating the course intramuscular of the accessory flexor carpi ulnaris muscle. A) flexor carpi ulnaris muscle; B) accessory flexor carpi ulnaris muscle; B<sub>1</sub>) proximal; B<sub>2</sub>) distal; C) flexor digitorum superficialis muscle; D) palmaris longus muscle; E) flexor carpi radialis muscle; F) radial artery; G) abductor muscle of the minimum finger; H) ulnar nerve; I) ulnar artery; J) palmaris brevis muscle was rebudded; L) abductor pollicis brevis muscle. Arrows (↑↓) indicate the itinerary of the tendon of the accessory muscle. Scale in centimeter.

part and muscular in its lower part. Additionally, the muscle belly was triple.

Nakahashi and Izumi (1987) cited a rare case of a short radiocarpal flexor found on the right forearm of a 47-year-old Japanese male corpse. The muscle arose from the anterior surface of the radius, ran distally in the deep layer of the flexor region to enter deeply into the carpal tunnel, and then interconnected with the subtendon of the extensor carpi radialis brevis at the gap between the bases of the second and third metacarpal bones.

Sakuma, Kato, Honda et al. (2004), tell they found a case of the absence of the tendon to the fourth toe of the extensor digitorum longus muscle of the right leg in the body of a 73-year-old Japanese woman during the course of dissection.

It is already evident that the muscles vary plenty as for his insert; they can be absentees, and many accessory muscles were described already (GARDNER, GRAY and O'RAHILLY, 1988), especially to the musculature of the hand (AYDINLIOGLU, SAKUL and DIYARBAKIRLI, 1998; D'COSTA, JIJI, SIVANADAN et al., 2006; NATSIS, LEVVA, TOTLIS et al., 2007; NAKANO, WATANABE and MASUTANI, 2003; SOLDADO-CARRERA, VILAR-COROMINA and RODRIGUEZ-BAEZA, 2000; WINDISCH, 2000) and forearm (CIGALI, KUTOGLU and CIKMAZ, 2002; HONG, 2005).

The variation of the accessory muscle of the flexor carpi ulnaris muscle described in our study differs relatively from those reported in our literature revision. However, the specific anatomic variations described may be anticipated and more readily recognized by hand surgeons during such open surgery, thus increasing the efficacy and safety of this common procedure.

## References

- AYDINLIOGLU, A., SAKUL, BU. and DIYARBAKIRLI, S. A rare insertion site for abductor pollicis longus and extensor pollicis brevis muscles. *Acta Anatomica*, 1998, vol. 163, p. 229-232.
- CIGALI, BS., KUTOGLU, T. and CIKMAZ, S. Musculus extensor digiti medii proprius and musculus extensor digitorum brevis manus - a case report of a rare variation. *Anatomia, Histologia, Embryologia*, 2002, vol. 31, no. 2, p. 126-127.
- D'COSTA, S., JIJI, PJ., SIVANADAN, R. and ABHISHEK A. Anomalous muscle belly to the index finger. *Annals of Anatomy*, 2006, vol. 188, p. 473-475.
- GARDNER, E., GRAY, DJ. and O'RAHILLY, R. *Anatomia: Estudo Regional do Corpo Humano*. 4 ed. Rio de Janeiro: Guanabara Koogan, 1988.
- HICKS, J. and NEWELL, R. Supernumerary muscles in the pectoral and axillary region, and the nature of the axillary arches. *Clinical Anatomy*, 1997, vol. 10, p. 211-212.
- HONG, MK. An uncommon form of the rare extensor carpi radialis accessorius. *Annals of Anatomy*, 2005, vol. 187, p. 89-92.
- KHALEDPOUR, C. and SCHINDELMEISER, J. Atypical course of the rare accessory extensor carpi radialis muscle. *Journal of Anatomy*, 1994, vol. 184, p. 161-163.
- KLEINERT, H. and HAYES, J. The ulnar tunnel syndrome. *Plastic Reconstructive Surgery*, 1971, vol. 47, p. 21-24.
- MOORE, KL. and DALLEY, AF. *Anatomia Orientada para a Clínica*. 4 ed. Rio de Janeiro: Guanabara Koogan, 2007.
- NAKAHASHI, T. and IZUMI, R. Anomalous interconnection between flexor and extensor carpi radialis tendons. *Anatomical Record*, 1987, vol. 218, p. 94-97.
- NAKANO, M., WATANABE, Y. and MASUTANI, M. A case of extensor digitorum brevis manus. *Dermatology Online*, 2003, vol. 9, p. 21.
- NATSIS, K., LEVVA, S., TOTLIS, T., ANASTASOPOULOS, N. and PARASKEVAS, G. Three-headed reversed plamaris longus muscle and its clinical significance. *Annals of Anatomy*, 2007, vol. 189, p. 97-101.
- OLAVE, E., DEL SOL, M., GABRIELLI, C., PRATES, JC. and RODRIGUES, CFS. The ulnar tunnel: a rare disposition of its contents. *Journal of Anatomy*, 1997, vol. 191, p. 615-616.
- SAKUMA, E., KATO, H., HONDA, N., MABUCHI, Y. and SOJI, T. A rare anomaly of the extensor digitorum longus. *Anatomical Science International*, 2004, vol. 79, p. 235-238.
- SCHJELDERUP, H. Aberrant muscle in the hand causing ulnar nerve compression. *Journal of Bone and Joint Surgery*, 1964, vol. 46B, p. 361.
- SOLDADO-CARRERA, F., VILAR-COROMINA, N. and RODRIGUEZ-BAEZA, A. An accessory belly of the abductor digiti minimi muscle: a case report and embryologic aspects. *Surgical and Radiologic Anatomy*, 2000, vol. 22, p. 51-54.
- WILLIAMS, PL., WARWICK, R., DYSON, M. and BANNISTER, LH. *Gray Anatomia*. Edinburgh: Churchill Livingstone, 1995.
- WINDISCH, G. The fourth lumbrical muscle in the hand: a variation of insertion on the fifth finger. *Surgical and Radiologic Anatomy*, 2000, vol. 22, p. 213-215.

Received July 20, 2009

Accepted May 15, 2010