

Morphological characteristics of foramen of Vesalius and its relationship with clinical implications

Rossi, AC.^{1*}, Freire, AR.¹, Prado, FB.¹, Caria, PHF.¹ and Botacin, PR.²

¹Department of Morphology, State University of Campinas – UNICAMP, Piracicaba, SP, Brazil

²Department of Basic Sciences, Paulista State University – UNESP, Araçatuba, SP, Brazil

*E-mail: rossi_anaclaudia@yahoo.com.br

Abstract

The aim of this study was to evaluate the incidence as well morphometry of the foramen of Vesalius in human skulls and analyzing their clinical importance. Dry human skulls (n = 80) and with gender distinction were used (40 male and 40 female). The results demonstrates an total incidence of 40%, 13.75% skulls with the bilateral presence of the foramen, 26.25% skulls with the unilateral presence of the foramen, 31.25% skulls with foramen only of the right side, 22.50% skulls with foramen only of the left side, 25% masculine skulls with at least 1 foramen and 52.25% skulls with at least 1 foramen. The morphometry showed an average diameter of 1.457 ± 1.043 mm on the right and 1592 ± 0938 mm to the left. The average distance to the foramen ovale was 1.853 ± 0.303 mm on the right side and 2.464 ± 0.311 mm on the left. It can be concluded that a deepened anatomical study of the foramen of Vesalius collaborates not only for anatomical knowledge of this structure, but also in clinical situations involving this foramen.

Keywords: foramen of Vesalius, emissary vein, thrombophlebitis, neurosurgery.

1 Introduction

The base of the skull has a lot of foramens, establishing communications between the extracranial and intracranial structures through the nerves and blood vessels, which pass through these structures. Among these foramina in the skull, there are foramens called emissaries, who allow the passage of emissary veins to carry blood between internal and external structures of the skull (SICHER and DU BRUL, 1977; GRAY et al., 1998; CRUZ-RIZZOLO and MADEIRA, 2006).

At the base of the skull an emissary foramen situated in the sphenoid bone and called "Foramen of Vesalius" (SHAPIRO and ROBINSON, 1967; SICHER and DU BRUL, 1977; GUPTA, RAY and GHOSH, 2005; WYSOCKI, REYMOND, SKARŻYŃSKI et al. (2006); SHINOHARA, MELO, SILVEIRA, et al., 2010) or sphenoid emissary foramen (RAMALHO, SOUSA-RODRIGUES, RODAS et al., 2007) and is considered unstable in several studies (SICHER and DU BRUL, 1977; GUPTA, RAY and GHOSH, 2005; WYSOCKI, REYMOND, SKARŻYŃSKI et al. (2006); (RAMALHO, SOUSA-RODRIGUES, RODAS et al., 2007); SHINOHARA, MELO, SILVEIRA, et al., 2010). Their position is anterior and medial in relation to foramen ovale (Figure 1 and 2) and allows the passage of an emissary vein communicating structures of the face, through the pterygoid plexus, to the cavernous sinus (SICHER and DU BRUL, 1977; GRAY et al., 1998; KOCAOGULLAR, AVCI, FOSSETT et al., 2003; RAYMOND et al., 2005).

Many studies were conducted to assess the importance of the presence of the emissary vein in this foramen, promoting a better understanding of the morphology of this structure (SHINOHARA, MELO, SILVEIRA, et al., 2010) that has importance in the spread of infection from extracranial origin into the skull (SICHER and DU BRUL, 1977) and also in neurosurgical techniques such as radiofrequency

rhizotomy (GUSMÃO, MAGALDI and ARANTES, 2003); (SHINOHARA, MELO, SILVEIRA ET AL., 2010).

This paper aims to analyze the incidence and morphological characteristics of human skull foramen in differentiating gender and a review of the clinical importance of this structure.

2 Methods

Eighty dry human skulls were analyzed for gender distinction of being divided into forty male skulls and forty female skulls. We evaluated the incidence of skulls with the anomaly, the anomaly bilaterally and unilaterally, in the presence of the right and left sides and finally the anomaly according to gender.

For morphometric analysis we used a manual caliper to measure the largest diameter of the foramen and its distance from the foramen ovale.

We used the mean \pm SEM for presentation of results. The data obtained were used for statistical analysis by t test and nonparametric test. The level of significance was $p < 0.05$.

3 Results

Of the 80 skulls examined in this study, 32 skulls had at least one foramen of Vesalius, resulting in an overall incidence of 40%. There were 11 skulls in the presence of the 21 bilaterally and unilaterally, resulting in incidence of 13.75 and 26.25%, respectively (Table 1). The total number of sides studied was 160, and 25 were found on the right side and 18 on the left, with an incidence of 15.62 and 11.25%, respectively. Regarding gender, 10 male skulls were found with at least one foramen, a total of 40 skulls, resulting in an incidence of 25% (Table 2). In the females, 21 skulls showed the presence

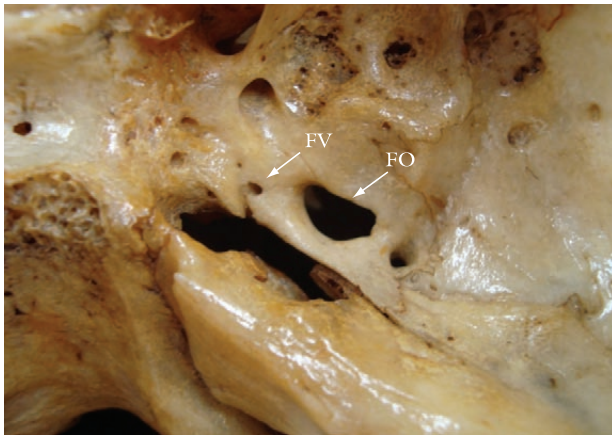


Figure 1. Internal view of skull showing the foramen of Vesalius (FV) positioned anterior and medial to the foramen ovale (FO) (indicated by the arrows).

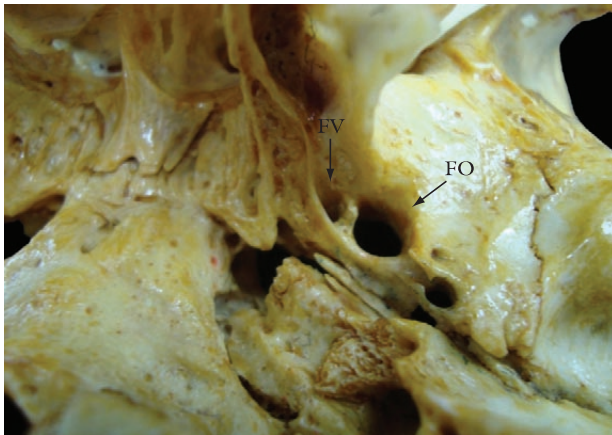


Figure 2. Inferior view of the base of skull showing the foramen of Vesalius (FV) positioned anterior and medial to the foramen ovale (FO) (indicated by the arrows).

of the foramen of Vesalius a total of 40 skulls, thus obtaining an incidence of 52.25% (Table 1). The foramen of Vesalius is a very small, with an average diameter of 1.457 ± 1.043 mm on the right and 1.592 ± 0.938 mm to the left. In addition, the distance from the foramen ovale, the anterior and medial direction, on average, was 1.853 ± 0.303 mm on the right side and 2.464 ± 0.311 mm on the left (Table 3). Statistical analysis of the diameter of the foramen on both sides was not statistically significant ($p < 0.05$).

4 Discussion

Many studies have reported the incidence of the foramen of Vesalius and noted that this foramen may have variations. In this study we found an incidence of 40% of skulls with the presence of the at least one foramen, regardless side and gender. Other studies have been conducted and were found higher incidences brought to our study, such as by Ramalho, Sousa-Rodrigues, Rodas et al. (2007) with analysis on 64 human skulls obtained incidence of 71.87% and Kaplan, Erol, Ozveren et al. (2007), who obtained 100% incidence, but with only 10 skulls examined. There were also minor incidences such as studies of Shinohara, Melo, Silveira et al., (2010) found the foramen to 33.75% in 400 skulls examined, a result close to that of Gupta, Ray and Ghosh (2005) and Boyd (1930) had as close to our data, 32.85 and 36.5%, respectively. Already Reymond, Charuta and Wysocki (2005) reported 22% incidence followed by Kodama, Inoue, Nagashima et al. (1997) (21.75%), Wysocki, Reymond, Skarżyński et al. (2006) with 17% incidence in 100 skulls and Williams, Bannister, Martin et al. (1995) the foramen was found in 8.5% of the skulls.

According to Bergman, Aww and Miyauchi (1995) and Lang et al. (1983), the foramen can be found in 40% of cases, an incidence similar to that of our study.

The presence of foramen on both sides (bilateral) was 13.75% in our study, a result close to the studies of Shinohara, Melo, Silveira et al. (2010) with 15.5% and Boyd (1930), with 12.5% incidence. Gupta, Ray and Gosh (2005) and Kodama, Inoue, Nagashima et al. (1997) found an incidence of 22%. Reymond, Charuta and Wysocki (2005) already obtained a low incidence of 5% of the skulls. Berge and Bergman (2001) found 35% of bilateral presence, a high incidence compared to other studies.

Already unilaterally found an incidence of 26.25% compared to the study of Gupta, Ray and Gosh, with 20% incidence. In the study of Shinohara, Melo, Silveira et al., (2010) the occurrence was 18.25% of the skulls.

Table 1. Incidence found in the analyzed skulls.

Groups	N	N (foramens)	Incidence (%)
Skulls with foramens	80	32	40
Skulls with foramens – bilateral	80	11	13.75
Skulls with foramens – unilateral	80	21	26.25
Skulls with foramens – male	40	10	25
Skulls with foramens – female	40	21	52.25

Table 2. Incidence found on the sides in the analyzed skulls.

Groups	N (sides)	N (foramens)	Incidence (%)
Skulls with foramens – right side	160	25	15.62
Skulls with foramens – left side	160	18	11.25

Table 3. Values of the diameters and distances between foramen of Vesalius (FV) – foramen ovale (FO).

Grupos	Average + SEM (mm)	Median (mm)
Diameter of the foramens – right side	1.457 ± 1.043	1.2
Diameter of the foramens – left side	1.592 ± 0.938	1.65
Distance FV – FO – right side	1.853 ± 0.303	1.4
Distance FV – FO – left side	2.464 ± 0.311	2.0

Bergman, Aww and Miyauchi (1995) reported the presence of this foramen unilateral in 13% of cases. According to a study by Kodama, Inoue, Nagashima et al. (1997) in skulls of adults, 5.5% had unilateral foramen. Ginsberg, Pruet, Chen et al. (1994) observed the presence unilateral in 80% of cases by CT scan of high resolution. Based on our results and other studies, gives results that faced with the studies that reported the incidence of bilateral foramen be greater than unilateral foramen in skulls (KODAMA, INOUE, NAGASHIMA et al., 1997; GUPTA, RAY and GOSH, 2005).

Andreas Vesalius (VESALIUS, 1543), in his famous book "De Humani Corporis Fabrica" says there is no significant difference in the frequency of occurrence between the unilateral right and left sides. But in our study we observed significant differences being 15.62% of the skulls with the presence of the right side and 11.25% of the left. Gupta, Ray and Gosh (2005) evaluated 70 sides of 35 adult human skulls, with distinction of gender and the foramen of Vesalius was present in 23 sides (14 right and 9 on the left) with an incidence of 32.85% (20% right side and 12.85% on the left).

Already Shinohara, Melo, Silveira et al., (2010) found an incidence of 7.75% on the right side and 10.5% on the left. Results close to those found by Boyd (1930), where the foramen was present on the right side in 10.6% and on the left side in 11.2%. Lang et al. (1983) found the foramen in 49% of skulls on the right side and 36% on the left. In cases of Shinohara, Melo, Silveira et al., (2010) was the presence of a double foramen was observed in 7 of the 400 skulls examined. This fact is remarkable when compared to the number stated by Boyd (1930), found that only 1 in 1000 were double skulls analyzed.

In our study we compared the presence of foramina between the genders. Found 25% of male skulls with foramen and 52.25% of female skulls with this structure, and thus a significant difference between genders, with greater presence in women.

Regarding the diameter, we found an average of 1.457 ± 1.043 mm on the right side and 1.592 ± 0.938 on the left. Shinohara, Melo, Silveira et al., (2010) found an average diameter in the right side of 0.69 mm (range 0.24-1.6 mm), and the left, the value was 0.72 mm (range 0.08-2.06 mm). According to Boyd (1930), in 65% of cases, foramen of Vesalius was 0.5 mm and, in most others, it was 1 mm. Only 5% was above 1 mm, in three cases was 2 mm and in one case was 2.5 mm. The average diameter found in the work of Kaplan, Erol, Ozveren et al. (2007) was 1 mm (range 0.8-1.2 mm). Lanzieri, Duchesneau, Rosenbloom et al. (1988) studied 50 CT scans of high resolution and found 1-2 mm size in 59% of CT scans. Lang et al. (1983) observed the foramen 2 mm in diameter.

In this study, the foramen of Vesalius was found at a distance to the foramen ovale from anterior to medial was 1.853 ± 0.303 mm on the right and 2.464 ± 0.311 mm on the left. The average distance between the foramen of Vesalius and the foramen ovale in the study of Shinohara, Melo, Silveira et al., (2010) was 2.55 mm on the right and 2.59 mm on the left side, close to the results of our study. Kaplan, Erol, Ozveren, et al. (2007) reported the foramen of Vesalius with a distance of 4 mm (range 3-5 mm) anterior and medial to the foramen ovale. According to Ramalho, Sousa-Rodrigues, Rodas et al. (2007), this measure is less than our results, they found 7 mm on the right and 6 mm on the left. In this study also was found a remarkable fusion of the foramen of Vesalius to the foramen ovale (Figure 3).

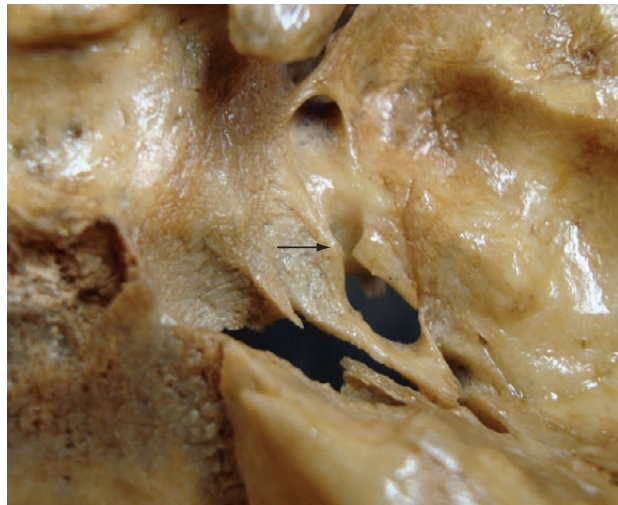

Figure 3. Internal view of skull showing the foramen of Vesalius partially fused with foramen ovale (indicated by the arrow).

4.1 Clinical considerations

The extra and intracranial veins communicate directly through small veins that pass through specific points on the skull bones, and called emissary veins (SICHER and DU BRUL, 1977). This small emissary vein in foramen of Vesalius drains the cavernous (KOCAOGULLAR, AVCI, FOSSETT et al., 2003) and, as the emissary veins other is a major player in the equalization of intracranial pressure and, under some conditions these veins can act as safety valves (BOYD, 1930). However, the emissary vein that runs through the foramen of Vesalius connects the pterygoid plexus to the cavernous sinus, thus, a septic thrombus of extracranial origin may reach the cavernous sinus developed a thrombophlebitis (SICHER and DU BRUL, 1977).

Although Vesalius had described the presence of this foramen as a rare phenomenon, its importance should be considered, because it becomes a more complicated surgery on the skull because of its variations. The recognition of anatomical structures and their possible variations will help in distinguishing normal from potentially abnormal structures during the computed tomography and magnetic resonance imaging.

For the treatment of trigeminal neuralgia, the approach through the foramen ovale through a technique called rhizotomy with conventional fluoroscopy to guide a needle puncture into the cavum of Meckel (GUSMÃO, MAGALDI and ARANTES, 2003; SHINOHARA, MELO, SILVEIRA, et al., 2010). In this technique, the needle can penetrate the foramen of Vesalius with puncture of the cavernous sinus. Sweett (1966), studying this technique used a needle and was placed in the foramen of Vesalius in 9 cases, 8 of which there were no negative consequences, but there was 1 case of bleeding in the temporal lobe. Sindou, Keravel, Abdennebi et al. (1987) reported error of needle puncture in the cavum of Meckel in 10 cases of a series of 200: 2 in the carotid canal, 1 in the jugular foramen and 7 in the Vesalius. Gusmão, Magaldi and Arantes (2003) argued that the problems of this technique are 0.5 to 4%, with an average of 2.7%.

5 Conclusion

In conclusion, the foramen of Vesalius presents substantial impact on being given importance in the study due not only to the anatomical knowledge of this structure, but also because of that present in the region where neurosurgical techniques are applied in addition to the presence emissary vein, which passes through this foramen, and its relation to the spread of infections.

References

- BERGE, JK. and BERGMAN, RA. Variations in size and in symmetry of foramina of the human skull. *Clinical Anatomy*, 2001, vol. 14, no. 6, p. 406-413.
- BERGMAN, RA., AFIFI, AK. and MIYAUCHI R. *Illustrated encyclopedia of human anatomic variation: opus V: skeletal systems: cranium*. 1995. (on-line)
- BOYD, GI. Emissary foramina of cranium in man and the anthropoids. *Journal of Anatomy*, 1930, vol. 65, no. 1, p. 108-121.
- GINSBERG, LE., PRUETT, SW., CHEN, MY. and ELSTER, AD. Skull base foramina of the middle cranial fossa: reassessment of normal variation with high-resolution CT. *American Journal of Neuroradiology*, 1994, vol. 15, no. 2, p. 283-291.
- GUPTA, N., RAY, B. and GHOSH, S. Anatomic characteristics of foramen Vesalius. *Kathmandu University Medical Journal*, 2005, vol. 3, no. 2, p. 155-158.
- GUSMÃO, S., MAGALDI, M. and ARANTES, A. Rizotomia trigeminal por radiofrequência para tratamento da neuralgia do trigêmeo. *Arquivo de Neuropsiquiatria*, 2003, vol. 61, no. 2, p. 434-440.
- KAPLAN, M., EROL, FS., OZVEREN, MF., TOPSAKAL, C., SAM, B. and TEKDEMIR, I. Review of complications due to foramen ovale puncture. *Journal of Clinical Neuroscience*, 2007, vol. 14, no. 6, p. 563-568.
- KOCAOGULLAR, Y., AVCI, E., FOSSETT, D. and CAPUTY, A. The extradural subtemporal keyhole approach to the sphenocavernous region: anatomic considerations. *Minim Invas Neurosurg*, 2003, vol. 46, no. 2, p. 100-105.
- KODAMA, K., INOUE, K., NAGASHIMA, M., MATSUMURA, G., WATANABE, S. and KODAMA, G. Studies on the foramen Vesalius in the Japanese juvenile and adult skulls. *Hokkaido Igaku Zasshi*, 1997, vol. 72, no. 6, p. 667-674.
- LANG, J. *Clinical anatomy of the head, neurocranium, orbit and craniocervical region*. Berlin: Springer, 1983.
- LANZIERI, CF., DUCHESNEAU, PM., ROSENBLOOM, SA., SMITH, AS. and ROSENBAUM, AE. The significance of asymmetry of the foramen of Vesalius. *American Journal of Neuroradiology*, 1988, vol. 9, no. 6, p. 1201-1204.
- RAMALHO, AJC., SOUSA-RODRIGUES, CF., RODAS, PMM., LINS, CJP., DE LIMA, RLL., ALMEIDA, ETDL. and NETO, JABS. A incidência e as relações morfométricas do forame emissário do esfenóide em crânios humanos. *International Journal of Morphology*, 2007, vol. 25, no. 1, p. 145.
- REYMOND, J., CHARUTA, A. and WYSOCKI, J. The morphology and morphometry of the foramina of the greater wing of the human sphenoid bone. *Folia Morphologica*, 2005, vol. 64, no. 3, p. 188-193.
- SHAPIRO, R. and ROBINSON, F. The foramina of the middle fossa: a phylogenetic, anatomic and pathologic study. *American Journal of Roentgenology*, 1967, vol. 101, no. 4, p. 779-794.
- SICHER, H. and DU BRUI, EL. *Anatomia bucal*. 6 ed. Rio de Janeiro: Guanabara Koogan, 1977.
- SINDOU, M., KERAVEL, Y., ABDENNEBI, B. and SZAPIRO, J. Traitement neuro-chirurgical de la névralgie trigéminal: abord direct ou méthode percutané? *Neuro-chirurgie*, 1987, vol. 33, no. 2, p. 89-111.
- SWEET, WH. Trigeminal neuralgias. In. ALLING, CC., *Facial pain*. Philadelphia: Lea & Febiger, 1968. p. 89-106.
- VESALIUS, A. *De humani corporis fabrica libri septem*. Basileae [Basel]: Ex officina Joannis Oporini, 1543.
- GRAY, H., BANNISTER, LH., BERRY, M. and WILLIAM, PL. Osteology. In. GRAY, H., BANNISTER, LH., BERRY, M. and WILLIAM, PL. *Gray's anatomy*. 38 ed. London: Churchill Livingstone, 1995. p. 344.
- WYSOCKI, J., REYMOND, J., SKARŻYŃSKI, H. and WRÓBEL, B. The size of selected human skull foramina in relation to skull capacity. *Folia Morphologica*. 2006, vol. 66, no. 4, p. 301-308.

Received December 22, 2009

Accepted July 2, 2010