

EVALUATION OF RAT TESTES TREATED WITH *ARCTIUM LAPPA* L: MORPHOMETRIC STUDY

Fabrcia S. Predes.¹, Juliana C. Monteiro¹, Tarcizio A. R. Paula², Srgio L. P. da Matta¹

¹Departamento de Biologia Geral, ²Departamento de Veterinria

Universidade Federal de Viosa, Av. PH Rolfs s/n - Campus Universitrio CEP: 36570 000
Viosa - MG

ABSTRACT

Arctium lappa L. (burdock) is a plant brought from Japan and acclimated in Brazil, which is widely used in popular medicine all over the world. This study was carried out to assess the possible effects of *A. lappa* in testes of adult Wistar rats. They received the extract in water bottles at doses of 10 or 20 g/L daily for 40 days. There were no significant alterations in the biometric data including body and accessory sexual organs weight and in the histometric data such as volume density of the testis compartments and Leydig cell morphometry. Unaltered histometric and biometric data shows that *A. lappa* did not cause impairment of spermatogenesis.

Key words: *A. lappa*, rat, testis, morphometry and biometry

INTRODUCTION

Arctium lappa L. (*Asteraceae*) is a plant brought from Japan and acclimated in Brazil, which is widely used in popular medicine all over the world [14]. This plant has long been cultivated as a vegetable for dietary use and is also used as a folk medicine, as a diuretic, antipyretic [2] and for hypertension, gout, hepatitis and other inflammatory disorders [11]. Several studies have reported that the *A. lappa* possesses various pharmaceutical activities including antibacterial activity [2, 14], antifungal activity [14], platelet anti-aggregating effect [11, 14], antioxidant action [2, 8, 14], hepatoprotective efficacy [10, 11] and anti-inflammatory activity [2, 9]. Additionally, Pereira et al. [14] have shown that *A. lappa* exhibits antimicrobial activity against oral microorganism. Pereira et al. [14] have shown that *A. lappa* exhibits antimicrobial activity against oral microorganism. In recent years, the crude water

extract of *A. lappa* named *A. lappa* tea, has become a promising and important beverage because it has ample therapeutic action [11], but no attention was paid to its possible effect on the reproductive system of mammals. It can be harmful to take herbal medicine without being aware of its potential adverse effects [1]. The present study was undertaken to assess the effect of *A. lappa* leaf extract on Wistar rat testes.

MATERIALS AND METHODS

Plant material

A. lappa leaves were obtained from Grupo Entre Folhas, of the Federal University of Viosa, Minas Gerais, Brazil in July 2001. The plant material was identified and a voucher specimen was deposited in the VIC Herbarium of the Department of Vegetal Biology, Federal University of Viosa, Minas Gerais, Brazil, as accession n°. 28960. Two aqueous extracts were obtained from the plant material by infusion prepared in the concentrations of 10 and 20 g of dried leaves/L of water. The aqueous extract submitted to lyophilization yielded, respectively, 0.21 and 0.42 % w/w.

*Correspondence to: Fabrcia de Souza Predes,
Departamento de Biologia Celular, Instituto de Biologia,
Universidade Estadual de Campinas-UNICAMP, CP. 6109, So Paulo, SP,
Brasil, 13083-863. Fax: + 55
19 3521611, Phone: +55 19 35216114 (e-mail: fpredes@yahoo.com.br).

Animals

The study was carried out on 100-day-old adult male Wistar rats (*Rattus norvegicus*), weighing between 220 and 275 g. They were obtained from the Department of Health and Nutrition (Federal University of Viçosa, Viçosa, MG, Brazil) and kept in individual cages in 12hrL:12hrD conditions. They were provided with food ad libitum for 40 days. These animals were handled and euthanized in accordance to Ethical Principles for Animal Research established by the Brazilian College for Animal Experimentation (COBEA).

Treatment

Thirty rats were randomly divided into three groups of ten animals each. All the animals received water and the extract in water bottles attached to the outside of the cage. The control group received only water. Group A and Group B daily received 200mL of leaf extract of *A. lappa* at a dose of 10g/L and 20g/L respectively [7]. The infusion was placed instead of water to coincide with the traditional method of preparation and was daily prepared from dry leaves.

Tissue Preparation

Rats were anesthetized with ether and the thoracic cavity opened for the perfusion-fixation by whole body perfusion. A needle was inserted into the aorta and 0.9% saline solution was injected to clear the blood vessels. After vessel clearance, a 2-way valve apparatus was used to introduce 2.5% glutaraldehyde (Synth. Labsynth) into the vessels of the animals for 25-30 min. Testes and seminal vesicles were removed and weighed. Testis tissue was refixed in the same fixative for 24 hours and prepared for embedding in glycol methacrylate (Historesin, Leica). Subsequently, sections of 4 μ m thickness were obtained and stained with toluidine blue/1% sodium borate.

Histometry and Morphometry

The testes were dissected to obtain the tunica albuginea and testis parenchyma weights (weights of testes minus tunica albuginea). The gonadosomatic index (GSI) was obtained from testis mass divided by the body weight of each animal. The volume density of testis compartments (intertubular and tubular compartments) was determined using a 494 intersec-

tion grid placed on the monitor showing the light microscopy image at 200x magnification. Twenty fields (9880 points) were scored for each animal. The volume density of various testicular tissue components were determined using a 494 intersection grid placed on the monitor revealing a light microscopy image at 400X magnification. Six thousand points were classified as one of the following: Leydig cell, blood vessels, lymphatic space or connective tissue. The volume of each component of the testis was determined as the product of the volume density and testis volume. For subsequent morphometric calculations, the specific gravity of testis tissue was considered to be 1.0 [4]. The tubular diameter and height of seminiferous tubule epithelium were measured at 100x magnification with the Image Pro Plus program associated to a Olympus BX-40 microscope. Thirty tubular profiles that were round or nearly round were chosen randomly and measured for each animal. The epithelium height was obtained with the same tubules used to determine tubular diameter. The total length of the seminiferous tubule, expressed in meters, was obtained by dividing seminiferous tubule volume by the squared radius of the tubule multiplied by the pi value [13]. These values were expressed per testis and per gram of testis. The average diameter of the Leydig cell nucleus was obtained from the assessment of 30 cells/animal in Image Pro Plus software associated to a Olympus BX-40 microscope. From this value, the $\frac{4}{3}\pi r^3$ formula was used, where r was the mean nucleus radius that was determined to estimate the nuclear volume of each Leydig cell. After the volume of the nucleus and its proportion in Leydig cell total volume was determined, the single cell volume was estimated. This value and the calculation of Leydig cell volume was used to calculate the total number of Leydig cells per testis and per gram of testis

Statistical analysis

Values were expressed as mean \pm S.E.M. (standard error mean). Statistical evaluation of significant difference between means was performed with one way analysis of variance (ANOVA) followed by the Duncan test. The significance level considered was $P < 0.05$.

RESULTS

Each animal drank approximately 50 ml of *A. lappa* extract per day (data not shown). The oral adminis-

tration of *A. lappa* extract did not alter body weight. However, the testis weight increased significantly in group A. The mean found for the tunica albuginea in treated animals was similar to the control. No changes were observed for testicular parenchyma and GSI. The tubular diameter, seminiferous epithelium height and total tubular length did not change after the treatment (Fig. 1A-C) (Table 1). The morphometric

measurement of volume density and testicular volume components were similar except for the connective tissue, where there was a significant increase in the treated groups compared with the control group (Table 2). No change in the average Leydig cell volume including nuclear and cytoplasmatic volume, nor in the number of these cells in the testis, could be detected in the groups studied (Table 3).

Table 1 – Biometric data e testis histometry of adults Wistar rats treated with different of *A. lappa* aqueous extract (mean \pm SEM).

Parameter	Control	Group A	Group B
Body weight (g)	248.42 \pm 3.45	255.71 \pm 1.45	244.56 \pm 2.41
Testes weight (g) ^a	2.450 \pm 0.28	2.625* \pm 0.043	2.486 \pm 0.031
Tunica albuginea (g) ^a	0.077 \pm 0.001	0.103 \pm 0.011	0.093 \pm 0.011
Seminal vesicle (g)	0.662 \pm 0.045	0.648 \pm 0.058	0.680 \pm 0.058
Gonadosomatic index (%)	1.023 \pm 0.018	1.067 \pm 0.017	1.057 \pm 0.015
Tubular diameter (μ m)	312 \pm 3.29	316.71 \pm 3.37	318.16 \pm 2.48
Seminiferous epithelium height (μ m)	111.92 \pm 4.35	112.33 \pm 3.79	110.35 \pm 3.38
Tubular lenght/ testis (m)	14.00 \pm 0.42	14.41 \pm 0.67	13.26 \pm 0.41
Tubular lenght/gram of testis (m)	11.44 \pm 0.28	10.79 \pm 0.37	10.66 \pm 0.19

^aRight and left

* Indicate significant differences (P < 0.05)

Table 2 - Volume (mL) and volume density (%; in parentheses) of the testis compartments of adult Wistar rats treated with different of *A. lappa* aqueous extract (mean \pm SEM).

Parameter	Control	Group A	Group B
Seminiferous tubule	1.17 \pm 0.02 (87.1)	1.14 \pm 0.03 (85.9)	1.05 \pm 0.03 (84.,7)
Intertubular compartment	0.16 \pm 0.01 (12.9)	0.19 \pm 0.01 (14.1)	0.19 \pm 0.02 (15.3)
Leydig cell	0.033 \pm 0.002 (2.7)	0.025 \pm 0.002 (1.8)	0.030 \pm 0.003 (2.4)
Connective tissue	0.017 \pm 0.004 (1.3)	0.046 \pm 0.005 (3.4)*	0.039 \pm 0.003 (3.,1)*
Blood vessels	0.017 \pm 0.003 (1.4)	0.021 \pm 0.003 (1.6)	0.016 \pm 0.003 (1.3)
Lymphatic vessels	0.093 \pm 0.004 (7.5)	0.098 \pm 0.005 (7.3)	0.105 \pm 0.005 (8.,5)

Table 3 - Leydig cell morphometry of adult Wistar rats treated with different concentrations of *A. lappa* aqueous extract (mean \pm SEM).

Parameter	Control	Group A	Group B
Nuclear diameter (μm)	7.56 \pm 0.09	7.15 \pm 0,31	6.89 \pm 0.36
Leydig cell volume (μm^3)	900.66 \pm 46.30	841.11 \pm 104,62	692.72 \pm 100.53
Nuclear volume (μm^3)	226.76 \pm 8.18	202.87 \pm 29,46	183.65 \pm 27.25
Cytoplasmatic volume (μm^3)	673.90 \pm 39.95	638.24 \pm 79,04	509.07 \pm 74.81
Leydig cell number/ testis (10^6)	37.4 \pm 3.39	31.3 \pm 0,34	56.9 \pm 1.40
Leydig cell number/ g of testis (10^6)	29.4 \pm 0.28	23.0 \pm 0,24	43.4 \pm 1.02

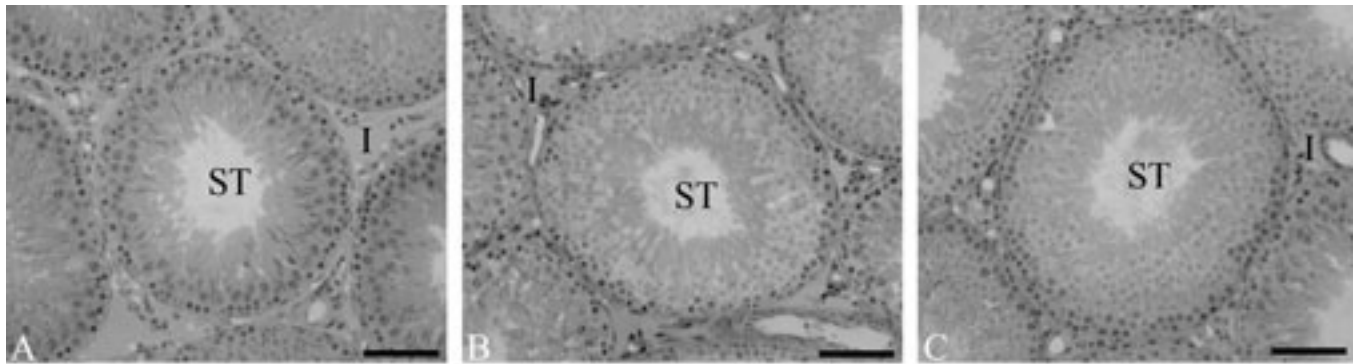


Figure 1- Testis of rats treated with different concentrations of *A. lappa* aqueous extract. a- Control Group. b- Group A (10g/L). c- Group B (20g/L). ST- seminiferous tubule; I- interstitium. Magnification 200X.

DISCUSSION

The present study was undertaken to assess the possible effects of the administration of *A. lappa* extract, in two different concentrations, on rat testes. *A. lappa* extract did not alter the body weight. Despite the long-term treatment, the results show nontoxicity as demonstrated by the unaltered body weight, which indicates normal functioning of vital organs and whole body. Although the testis weight of group A increased, this alteration could not be the effect of the treatment since group B received a higher concentration of the extract and did not have a significant weight change. Also, the parenchyma and albuginea weight were not altered following *A. lappa* treatment. Testis weight or size generally establishes the normalcy of testes, enabling experimentally induced changes in testicular size to be assessed [5]. The results above show that this plant did not alter the normalcy of the testis. The testis is an extremely heterogeneous organ, containing numerous compartments and cell types. The testis mainly consists of the seminiferous tubules in which spermatogenesis takes place, and the space between the tubules, the interstitium, which has, among others, an endocrine function [6]. Quantitative data obtained in some structural components of the testes in the present study are in agreement with that available from previous studies. For example, the volume density of seminiferous tubules [12, 13, 15] and Leydig cells [6, 12]. However, when we compared the volume density of other testicular components to

previous studies, the measurements were inconsistent. According to Russell and França [15], this can be explained by the considerable interlaboratory and intralaboratory variability in the data for any one morphometric parameter studied. There are a variety of reasons for the variability found which are probably associated with the approach used: a variability of morphometric techniques and the amount of sampling used. The structural parameters, testis size, tubular diameter and seminiferous tubule volume density is related to the total seminiferous tubule length. Additionally, a positive relationship usually exists between the tubular diameter and the spermatogenic activity of the testis [5]. As observed by morphometry, this variable did not change significantly after the treatment, suggesting that the plant caused no spermatogenesis impairment. The Leydig cells are the most important component of the interstitial compartment and their main function is production of steroid hormones [6]. In spite of the considerable technical differences between previous studies and the present one, the volume and number of Leydig cells are intermediate, between the value observed by Mori and Christensen [12] and Kim and Yang [6] in their work with normal animals. It shows that treatment with *A. lappa* did not change the morphometry of Leydig cells. The unaltered weight of the seminal vesicle confirms that the endocrine function was not impaired since, according to Creasy [3], the seminal vesicle weight is an indicator of normal function of these cells. The present study shows the non-toxicity of the plant tested, as shown by the unal-

tered body weight which indicates normal functioning of vital organs including testis and accessory reproductive glands. Unaltered histometric and biometric data shows that *A. lappa* did not cause impairment of spermatogenesis.

ACKNOWLEDGEMENTS

The authors gratefully acknowledge Dra. Heidi Dolder for correcting the English. This study was supported by CNPq.

REFERENCES

1. Capasso R, Izzo AA, Pinto L, Bifulco T, Vitobello C, Mascolo N (2000) Phytotherapy and quality of herbal medicines. *Fitoterapia* **71**, 58-65.
2. Chen F, Wu A, Chen C (2004) The influence of different treatments on the free radical scavenging activity of burdock and variations of its active components. *Food Chem.* **86**, 479-484.
3. Creasy DM (2001) Pathogenesis of Male Reproductive Toxicity. *Toxicol. Pathol.* **29**, 64-76.
4. França LR, Godinho CL (2003) Testis morphometry, seminiferous epithelium cycle length, and daily sperm production in domestic cats (*Felis catus*). *Biol. Reprod.* **68**, 1556-1561.
5. França LR, Russell LD (1998) The testes of domestic animals. In: Male reproduction. A multidisciplinary overview. (Regadera J, Martinez-Garcia, eds). p. 197-219. Churchill Livingstone: Madrid.
6. Kim I, Yang H (1999) Morphometric study of the testicular interstitium of rats during postnatal development. *The Korean J. Anat.* **32**, 849-858.
7. Franco, I.F. & Fontana, V.L. (2002), *Ervas & Plantas. A medicina dos simples*. Livraria Vida, Erxim, p. 208
8. Leonard SS, Keil D, Mehlman T, Proper S, Shi X, Harris GK (2006) Essiac tea: Scavenging of reactive oxygen species and effects on DNA damage. *J. Ethnopharmacol.* **103**, 288-296.
9. Lin CC, Lu JM, Yang JJ, Chuang SC, Ujiie T (1996) Anti-inflammatory and radical scavenge effects of *Arctium lappa*. *Am. J. Chin. Med.* **24**, 127-137.
10. Lin SC, Chung TC, Lin CC, Ueng TH, Lin YH, Lin SY, Wang LY (2000) Hepatoprotective effects of *Arctium lappa* on carbon tetrachloride- and acetaminophen- induced liver damage. *A. J. Chin. Med.* **28**, 163-173.
11. Lin SC, Lin CH, Lin CC, Lin YH, Chen CF, Chen IC, Wang LY (2002) Hepatoprotective effects of *Arctium lappa* Linne on liver injuries induced by chronic ethanol consumption and potentiated by 10 carbon tetrachloride. *J. Biomed. Sci.* **9**, 401-409.
12. Mori H, Christensen AK (1980) Morphometric analysis of Leydig cells in the normal rat testis. *J. Cell Biol.* **84**, 340-354.
13. Russell LD, Ettlin RA, Sinha- Hikim AP, Clegg (eds) (1990) *Histological and histopathological evaluation of the testis* Cache River Press: Clearwater.
14. Pereira JV, Bergamo DCB, Pereira JO, França SC, Pietro RCLR, Silva-Souza YTC (2005) Antimicrobial activity of *Arctium lappa* constituents against microorganisms commonly found in endodontic infections. *Braz. Dent. Journal* **16**, 192-196.
15. Russell LD, França LR (1995) Building a testis. *Tissue Cell.* **27**, 129-147.