

Unilateral incomplete bifid ureter: a case report

KUMAR, V. * and REMYA, V.

K S Hegde Medical Academy, 575018, Mangalore, India

*E-mail: vishalkumarnd@gmail.com

Abstract

Introduction: There are many congenital anomalies of ureter has been described in various literatures. This kind of anomaly is takes special importance because they remain asymptomatic or clinically present as pyelonephritis or urinary lithiasis. Even information of this kind of variation is very useful for radiological diagnosis. **Case Report:** We have observed a right sided incomplete bifid ureter during dissection done for under graduates in our institution. The renal pelvis and ureter up to the pelvic brim was double and they were fused at the level of pelvic brim to form a single ureter. It finally opens into left lateral angle of the base of the urinary bladder by a single opening. **Discussion:** Normally ureter is a long tubular structure measuring 25-30 cm extending from renal pelvis to base of the urinary bladder, having thick muscular wall and a narrow lumen. Developmental variations like early splitting of ureteral bud can lead to such kind of anomaly. The incidence of bifid ureter is 0.5-3.0%. Thus early diagnosis of such asymptomatic conditions will prevent future complications and aid successful treatment.

Keywords: pyelogram, renal transplant, uretric bud, urinary bladder, urogram.

1 Introduction

Ureter is a long tubular structure extending from renal pelvis to urinary bladder measuring 25-30 cm. It has thick muscular wall and a narrow lumen. Superiorly it is continuous with funnel shaped structure called renal pelvis through which it communicates with secreting part of kidney. Inferiorly it opens into the lateral angle of the base of the urinary bladder. Ureter has upper part called abdominal part which runs down wards in the posterior abdomen wall up to pelvic brim. Lower part called pelvic part extends from pelvic brim to trigonal angle of urinary bladder (STANDRING, 2008). Ureter develops from the ureteric bud, as a diverticulum from the mesonephric duct around the 5th week of intra uterine life. The ureteric bud bifurcates when it comes into contact with the metanephric blastema (MOORE and PERSAUD, 1998).

Most of the cases reported have other associated variations. But here we have not observed any other anomaly other than incomplete unilateral bifid ureter. Such cases may remain asymptomatic throughout life, unless they produce some complications like frequent urinary tract infection, calculi, uretero ureteric reflux, ureteric stenosis, pyelonephritis (DAS, DHAR and MEHRA, 2011).

This kind of variations running in the same family is though rare. Seven such families had been identified (ATWELL, COOK, HOWELL et al., 1974). Incomplete duplication or bifid ureter is three times more common than complete duplication (MANDAL, GUPTA, CHAKRABORTY et al. 2012). Thus they impose immense risk to operating surgeons or can puzzle radiologists. So it makes it very useful to have some light on such variations.

2 Case Report

During the routine dissection of an adult male cadaver for undergraduate students in our college under Nitte University, we observed an unusual variation. The left renal pelvis and

ureter was partially split into two (Figures 1 and 2). The renal pelvis and ureter up to the pelvic brim was double and they were fused at the level of pelvic brim to form a single ureter (Figure 1). It finally opens into the urinary bladder through its left lateral trigonal angle by a single opening. The total length of ureter including renal pelvis is 25 cm. The length of split region is 17 cm. The renal pelvis and ureter of the right side is normal. The shapes of kidney were normal. There were no any variations in renal vessels observed.

3 Discussion

Ureter starts developing from the ureteric bud in 5th week of intrauterine life as a diverticulum from dorsomedial side of the mesonephric duct. It grows upwards towards metanephric tissue. The ureteric bud bifurcates when it comes in contact with the metanephric blastema, induced by glial cell line derived neurotrophic factor (GDNF). Subsequent divisions of the ureteric bud and the mesenchyme form the gross structure of the kidney with major and minor calyces. The developing ureteric wall is highly permeable at an early stage. Its lumen becomes obliterated later and subsequently gets re canalized. Both processes begin at intermediate levels of the ureter and proceed cranially and caudally. Two usiform enlargements appear at the lumbar and pelvic levels of the ureter (CHAWLA, GUPTA, SINGH et al., 2014). Lack of GDNF or premature splitting of the uretral bud before it reaches to the nephrogenic cells gives rise to incomplete or branched ureter. Early splitting may give rise to complete duplication of ureter (HAWTHORNE, 1936).

Among the 0.1-0.2% abnormal fetuses which are detected during the inutero ultrasound procedures, 20-30% is anomalies of the genitourinary tract. Such abnormalities can be detected as early as 12-15 weeks gestation (CHAWLA, GUPTA, SINGH et al., 2014). In two-thirds of the cases, ureteral duplication

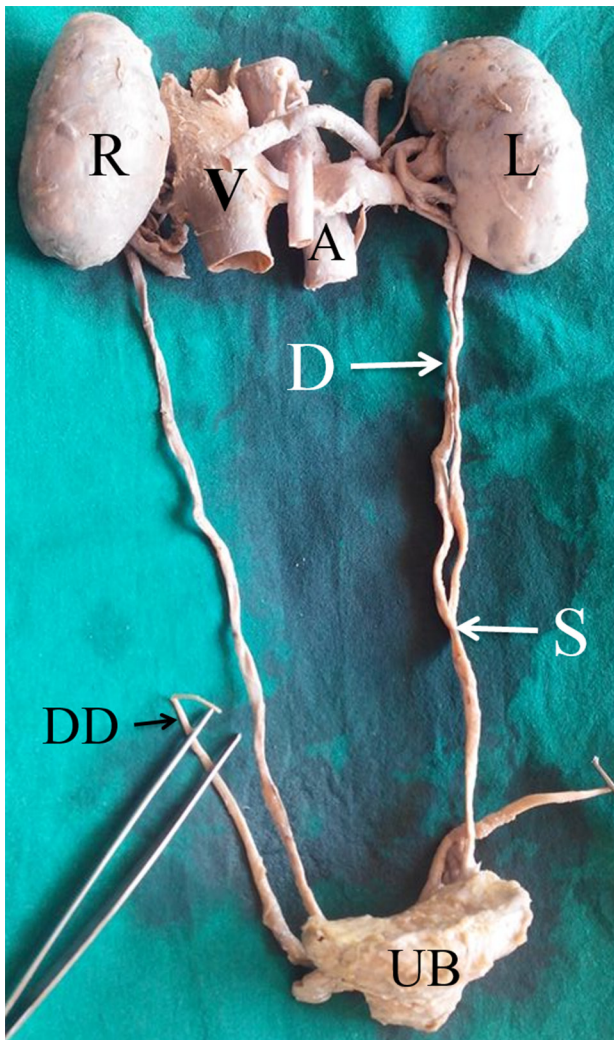


Figure 1. Anterior view of incomplete bifid ureter. R - Right Kidney; L - Left Kidney; V - Inferior vena cava; A - Abdominal aorta; D - Double ureter; S - Site of union of ureter; UB - Urinary bladder; DD - Ductus deferens.

is incomplete (GUPTA, GALHOTRA and SAGGAR, 2013). Based on data published by urograms, partially duplicated systems are three times more common than complete ones (BHAMANI and SRIVASTAVA, 2013). Author has quoted some cases where main ureter is branched into three, four and even five divisions (HAWTHORNE, 1936).

One of the author reported unilateral quadruplication of ureter which is a very rare condition (BHANDARKAR, RAJU and RAO, 1997).

Ureteral triplication and contralateral duplication, rare congenital anomaly of the urinary tract. Since its first description, only about 100 cases have been reported in the literature.

Ureteral quadruplication is a very rare case reported (SÖYLEMEZ, KOPLAY, ALTUNOLUK et al. 2011). This is the first case described in Cameroon, central Africa, and apparently the 13th worldwide (AKABA, NKODO, FOU DA et al., 2013).

In clinical practice, it has been found that duplicated collecting systems are two times more common in women compared with men (CHAWLA, GUPTA, SINGH et al., 2014). It was also found that there was a one in eight possibility that a child

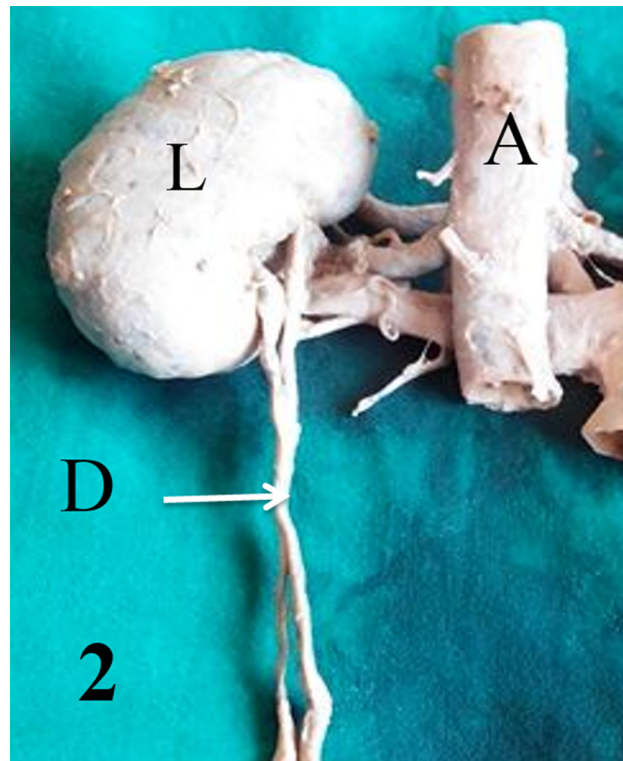


Figure 2. Posterior view of bifid renal pelvis. L - Left Kidney; A - Abdominal aorta; D - Double ureter.

with duplicated ureters would have a parent or sibling who was similarly affected (BHAMANI and SRIVASTAVA, 2013).

It is well recognised fact that an abnormal organ is more liable to disease than a normal one, so the possibility of this kind of variation should be kept in mind while treating (HAWTHORNE, 1936). While many patients are asymptomatic or have only mild symptoms (BHATTACHARYYA, BASU and SAMANTA, 2005).

Most duplication cases are incomplete with the ureters joining above their origin in the bladder. Such systems are prone to ureteroureteral reflux (WU, SNOW and TAYLOR, 1986). A duplex urinary tract is prone to infection, either from obstruction associated with an ectopic ureter or from vesico ureteric reflux (ATWELL, COOK, HOWELL et al., 1974).

Ureteroureteral reflux may occur in as many as 80% of cases. Severe reflux may be associated with a loss of cortical function in the affected renal segment. Partial duplication is usually diagnosed in adults and most of the cases present with hydronephrosis and recurrent urinary tract infection (GUPTA, GALHOTRA and SAGGAR, 2013).

Retrograde pyelogram can be a good tool than intravenous pyelogram to detect such anomaly. (HAWTHORNE, 1936) The author reported a rare case of bilateral incomplete double ureters. Initially based on Intravenous urography right side was shown as partial ureteric duplication, while left side was complete ureteric duplication. However, 3-dimensional CT urography, reconstructed using 16-multidetector computed tomography (CT), demonstrated bilateral incomplete double ureters (LEE, KIM, KANG et al., 2007).

Presence of such anomaly usually goes unnoticed with minor complaint of patient. In such situation it is better for clinicians to suspect this kind of anomaly. This information is

also very use full to radiologists for early detection. Thus early intervention may decrease future complications of the collecting system and decreases the morbidity and mortality significantly.

Acknowledgements: Dr. Palaksha KJ helping me us in collecting articles and for his valuable suggestions.

References

- AKABA, D., NKODO, JMM., FOU DA, PJ. and OB'OYONO, JM. Proximal ureteral quadruplication in combination with ureteral cyst: a case report. *Health Sciences and Disease*, 2013, vol. 14, n. 1, p. 54-57.
- ATWELL, JD., COOK, PL., HOWELL, CJ., HYDE, I. and PARKER, BC. Familial incidence of bifid and double ureters. *Archives of Disease in Childhood*, 1974, vol. 49, n. 5, p. 390-393. <http://dx.doi.org/10.1136/adc.49.5.390>. PMID:4834020.
- BHAMANI, A. and SRIVASTAVA, M. Obstructed bifid ureteric system causing unilateral hydronephrosis. *Reviews in Urology*, 2013, vol. 15, n. 3, p. 131-134. PMID:24223026.
- BHANDARKAR, AD., RAJU, AM. and RAO, MS. RAO MS Single unilateral ectopic bifid ureter with contralateral orthotopic quadrifid ureter- a rare combination. *Journal of Postgraduate Medicine*, 1997, vol. 43, n. 4, p. 104-105. PMID:10740737.
- BHATTACHARYYA, B., BASU, KS. and SAMANTA, N. Unilateral ureteral triplication with duplex kidney and megaureter. *Journal of Indian Association of Pediatric Surgeons*, 2005, vol. 10, n. 2, p. 108-111. <http://dx.doi.org/10.4103/0971-9261.16475>.
- CHAWLA, K., GUPTA, R., SINGH, HJ., GUPTA, T., AGGARWAL, A. and SAHNI, D. Bilateral bifid ureter with unilateral renal vasculature variations. *Surgical and Radiologic Anatomy*, 2014, vol. 36, n. 4, p. 393-396. <http://dx.doi.org/10.1007/s00276-013-1170-9>. PMID:23873247.
- DAS, S., DHAR, P. and MEHRA, RD. Unilateral isolated bifid ureter: a case report. *Journal of the Anatomical Society of India*, 2001, vol. 50, n. 1, p. 43-44.
- GUPTA, K., GALHOTRA, R. and SAGGAR, K. Yo-yo reflux in partial duplication of ureter: a diagnosis on the color and pulse Doppler study. *Muller J Med Sci Res*, 2013, vol. 4, n. 1, p. 116-118. <http://dx.doi.org/10.4103/0975-9727.118243>.
- HAWTHORNE, AB. The embryological and clinical aspect of double ureter. *Canadian Medical Association Journal*, 1936, vol. 34, n. 1, p. 21-26. PMID:20320125.
- LEE, S., KIM, W., KANG, KP., JEONG, YB., KIM, YK., JANG, YB. and PARK, SK. Bilateral incomplete double ureters. *Nephrology, Dialysis, Transplantation*, 2007, vol. 22, n. 9, p. 2720-2721. <http://dx.doi.org/10.1093/ndt/gfm303>. PMID:17556422.
- MANDAL, L., GUPTA, I., CHAKRABORTY, N. and RAY, A. Bifid ureter with anomalous renal and testicular vessels. *Diag Ther Stud*, 2012, vol. 1, n. 1, p. 7-12.
- MOORE, KL. and PERSAUD, TVN. *The developing human: clinically oriented embryology*. 6th ed. London: W. B. Saunders Company, 1998. p. 308-314.
- SÖYLEMEZ, H., KOPLAY, M., ALTUNOLUK, B. and FATİH OĞUZ, F. Ureteral triplication and contralateral duplication with vesicoureteral reflux. *Balkan Medical Journal*, 2011, vol. 28, p. 469-470.
- STANDRING, S. *Gray's anatomy*. 40th ed. New York: Churchill Livingstone Elsevier, 2008. p. 1238-1241.
- WU, F., SNOW, B. and TAYLOR, A Jr. A potential pitfall of DMSA scintigraphy in patients with ureteral duplication. *Journal of Nuclear Medicine*, 1986, vol. 27, n. 7, p. 1154-1156. PMID:3014087.

Received July 18, 2014
Accepted November 19, 2015