

Anatomy of sciatic nerve bifurcation in popliteal fossa: a fetal study

Sinha, MB.^{1*}, Gupta, R.², Aggarwal, A.², Sahni, D.², Sinha, HP.³

¹Department of Anatomy, All India Institute of Medical Sciences, Raipur, C.G., India, PIN-492099

²Department of Anatomy, Postgraduate Institute of Medical Education and Research, Pin- 160 012, Chandigarh, India

³Department of Neurology, Postgraduate Institute of Medical Education and Research, Pin- 160 012, Chandigarh, India

*E-mail: manishab80@gmail.com

Abstract

Background: We studied the bifurcation of sciatic nerve into two components which change their position throughout the early period of life. We proposed dimensions that would help reducing failure rates of anesthesia in popliteal fossa region and screening of malignancy related to sciatic nerve. **Methods:** The back of thigh and popliteal fossa of both sides of 50 fetuses (24 male and 26 female) were dissected. Skin over the gluteal region was dissected upto back of the knee. Sciatic nerve was traced from gluteal region to back of the thigh. The level where common fibular nerve and tibial nerve diverge from sciatic nerve and the diameter of sciatic nerve at various levels were evaluated. **Results:** In 97.7% (41/42) specimens, the bifurcation was above (5.1-20.86 mm) and in 2.3% (1/42) specimens, it was below (2.37 mm) the lateral condyle of femur. In 66% cases, sciatic nerve splits into two at or within 11 mm proximal to lateral condyle, while in 75% cases within 13mm, and in 100% cases within 21mm proximal to lateral condyle. **Conclusion:** This study provides quantitative data about the sciatic nerve in the gluteal region and back of the thigh. This data has a significant implication in diagnostic and anesthetic practice.

Keywords: sciatic nerve, bifurcation, diameter, fetus, popliteal fossa.

1 Introduction

The sciatic nerve, a branch of sacral plexus, leaves the pelvis and passes usually below the piriformis and bifurcates into two separate components at variable distance from popliteal fossa. In infant and children, for foot and ankle surgeries, two approaches are used for sciatic nerve block in popliteal fossa. Lateral approach is used in supine position, while posterior approach is used in prone position. Both the methods have their own merits and demerits. With increasing interest in the use of continuous block for acute post operative management, specific continuous sciatic block have been developed. From anatomical point of view, various factors like diameter, presence in common epineural sheath, appropriate distance of bifurcation from bony landmark affect sciatic nerve block in popliteal fossa (VOLKA, HADZIC, APRIL et al., 2001). Sciatic neuropathy is a result of injuries to sciatic nerve, leading to neurological deficits. Its long course makes it vulnerable to nerve injury from various causes (YUEN and SO, 1999) which needs repair.

As there is dearth of information on anatomy of bifurcation of sciatic nerve in fetuses, we examined the anatomical variations of the sciatic nerve in popliteal fossa and determined optimal distance from lateral lower end of femur. Aim of our study was to correlate distance of bifurcation of two components of sciatic nerve from lateral condyle with crown-heel length, hence to study growth of bifurcation with limb length. We also measured the diameter of sciatic nerve at various levels. This data would be useful for screening, grafting and anesthetic purposes and for repair.

2 Materials and Methods

After getting approval from institutional ethics committee and informed parental consent, both lower extremities of 50 fetuses, without any apparent congenital anomalies (24 male and 26 female) between age of 20 and 36 weeks were dissected. All the fetuses studied were those from spontaneously aborted materials provided by department of pathology, Postgraduate Institute of Medical Education and Research, Chandigarh. The fetuses used in this study were selected mainly from abortion material diagnosed as placental insufficiency. Materials were preserved in 10% formalin in the department of Anatomy of the institute. Skin over the gluteal region was dissected upto back of the knee. Gluteus maximus was cut open and the sciatic nerve was traced from gluteal region to the popliteal fossa (Figure 1). All micro-dissection of lower extremity was carried out under 2.5X loupe magnifying lense. The specimens were sketched and photographed with digital camera (DSC- W90, 8.1 Megapixel, Cybershot, Sony, Japan). All parameters were measured twice by two of the authors using vernier calipers (Mitutoyo corporation, Japan; accurate to 0.02mm) and mean was calculated.

2.1 Statistical analysis

The data obtained from the study was compiled and expressed as mean \pm standard deviation. For paired variables having normal distribution, paired t test was used. A *p* value of <0.05 was taken as significant.

3 Results

Out of 50 fetuses, eight fetuses had bifurcation just below piriformis. These were excluded from the study. Mean, SD and range of various parameters are summarized in Table 1. All parameters were normally distributed. The lateral length of femur was 76.69 mm (60.08-96.5 mm), distance of bifurcation from lateral condyle was 11.10 mm (-2.37-20.86 mm). Distance of bifurcation was falling 1/7th of limb length and was more distal than in the adults. In 97.7% (41/42) specimens, bifurcation was above (5.1-20.86 mm) and 2.3% (1/42) specimens, it was below (2.37 mm) the lateral condyle of femur. In 66% cases, sciatic nerve splits into two at or within 11 mm, while in 75% cases at 13mm, and in 100% cases within 21mm proximal to lateral condyle (Figure 1). Diameter at various points was tapering from proximal to distal (Table 1), showing some degree of positive correlation ($r>0$) with crown-heel length and lateral length of femur (Table 2). The association appears to be strong between sciatic nerve diameter at point of emergence and crown-heel length ($r>0.5$). At other points, the correlation was weak ($r<0.5$). Correlation of lateral length of femur to crown-heel length is strong ($r>0.8$). T test did not show any statistically significant difference between measurements of right and left side and between two sexes.

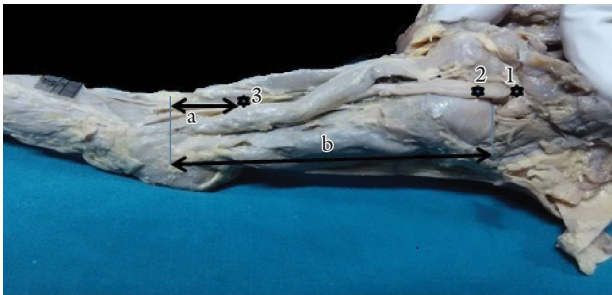


Figure 1. Measured parameters of sciatic nerve (SN). Diameter of SN at emergence to piriformis (1*), at greater trochanter level (2*), and at just before bifurcation (3*). a- distance from lateral condyle (LT) to bifurcation of sciatic nerve, b- Distance from greater trochanter (GT) to lateral condyle (LT).

4 Discussion

This study proposes distances from landmark for needle insertion for posterior and lateral approaches to block sciatic nerve in a newborn. For popliteal block, identification of lateral condyle as a bony landmark or popliteal crease as a soft tissue landmark is indispensable. Continuous popliteal block in infants and young children is the main indication in cases of club foot soft tissue releases (BERNIERE, SCHRAJER, PIANA et al., 2008). This is preferably blocked in popliteal fossa for lower limb surgeries below knee and also for postoperative analgesia. Furthermore, anatomical variations in the bifurcation level of sciatic nerve at back of the thigh have been suspected as a possible cause of incomplete block. Ultrasonography and nerve stimulator are used to keep an eye on sciatic nerve. However, due to the cost and lack of universal availability of equipment, and expertise in peripheral centers, practitioners still rely on anatomical landmarks. Location of bifurcation of sciatic nerve into two cannot be underestimated both in posterior and lateral approach of popliteal fossa block. Improved landmarks that more accurately predict the position of targeted nerve or plexus will potentially decrease the number of needle insertion and the time to perform peripheral nerve blocks as well as improved patient comfort. Bony landmark may have the advantage of better visualization with ultrasound than soft tissue landmarks. Our study provided distances from bony landmark or diameter at that levels.

Sciatic nerve has two terminal branches- common peroneal and tibial nerves. In our study, bifurcation level from lateral condyle in term fetuses ranged from -2.37mm to 20.86 mm. In 97.7% cases, the level was above (5.1-20.86mm) and 2.3% below (2.37mm) the lateral condyle of femur. Kurtoglu, Aktekin and Uluutku (2006) also encountered greater incidence of distal bifurcation. They reported the bifurcation above in 85% of cases and below the popliteal crease in 15% of cases in fetuses. Distal bifurcation is more common in our study which may be related to larger number of smaller fetuses in our study. As the intrauterine age advances, the bifurcation of sciatic nerve acquires more and more higher

Table 1. Results of anatomical measurements.

	Distances	Mean±SD (mm)	Range(mm)
1	Crown heel length	400.95±5.65	310-500
2	Distance between lateral condyle and GT	76.69±10.76	60.08-96.5
3	Distance between lateral condyle and bifurcation	11.10±3.6	-2.37-20.86
4	Diameter of sciatic nerve at point of emergence	4.36±1.09	2.5-7.2
5	Diameter of sciatic nerve at GT-IT (greater trochanter to ischial tuberosity) level	3.79±0.73	2.52-5.59
6	Diameter of sciatic nerve at point of bifurcation	2.53± 0.66	1.3-4.04

Table 2. Correlation of sciatic nerve diameter at various level and other anthropometric parameters.

Anthropometric parameters	Diameter of sciatic nerve at point of emergence		Diameter of sciatic nerve at GT-IT (greater trochanter to ischial tuberosity) level		Diameter of sciatic nerve at point of bifurcation		Crown heel length	
	R	R ²	R	R ²	R	R ²	R	R ²
Crown heel length	0.514888	0.2651	0.414421	0.17174	0.474464	0.22511	1.000	1
Lateral length of femur	0.470438	0.2213	0.407756	0.16626	0.491757	0.24182	0.8468	0.71707

level above the lateral condyle. In 66% cases, sciatic nerve splits into two within a distance of 11mm, while in 75% cases within 13mm and in all cases within 21 mm proximal to lateral condyle. In adults, in 57% of specimens, the sciatic nerve divides within 70 mm of popliteal crease, in 75% cases within 81 mm and in all cases within 115 mm (VOLKA, HADZIC, APRIL et al., 2001).

The diameter of sciatic nerve at various levels did not having any correlation with crown-heel length. In adults, the diameter of sciatic nerve just below piriformis is 20 mm which is five times of fetus near term. However, we could not find any study on sciatic nerve diameter in fetuses for comparison. Sciatic nerve and peroneal nerve are the most frequently injured nerves of the lower extremity. The cause of their injuries are numerous; fractures of femur and hip joint region, hip joint arthroplasty, infection, gunshot wounds, compression, iatrogenic injuries etc. (KOROMPILIA, PAYATAKES, BERIS et al., 2006). This study provides dimensions of the nerve for grafting in case of injuries and diagnosing tumors. Sciatic nerve is also under consideration as an important graft in place of optic nerve (CHAU, SO, TAY et al., 2000). Knowledge about morphometric anatomy of sciatic nerve is necessary for the diagnostic application of ultrasound and MRI as well as successful surgical resection and grafting. Best option for potential recovery of function is early identification giving the opportunity to proceed with resection and nerve graft (GRUEN, MITCHELL and KLINE, 1998). A rare case of intraneural perineuroma of sciatic nerve in early childhood was detected late (ØSTERGAARD, SMITH and STAUSBØL-GRØN, 2009) which could have been detected with the use of ultrasound if we had an idea of the diameter of sciatic nerve at various levels in different age groups. Hence, both distance of bifurcation and diameters of sciatic nerve obtained from the current study are of great clinical importance in ruling out malignancy of the nerve and for the purpose of anesthesia.

References

- BERNIERE, J., SCHRAJER, S., PIANA, F., VIALLE, R. and MURAT, I. A new formula of age-related anatomical landmarks for blockade of sciatic nerve in the popliteal fossa in children using the posterior approach. *Pediatric Anesthesia*, 2008, vol. 18, n. 7, p. 602-605. PMID:18482231. <http://dx.doi.org/10.1111/j.1460-9592.2008.02634.x>
- CHAU, WK., SO, KF., TAY, D. and DOCKERY, P. A morphometric study of optic axons regenerated in a sciatic nerve graft of adult rats. *Restorative Neurology & Neuroscience*, 2000, vol. 16, n. 2, p. 105-116. PMID:12671213
- GRUEN, JP., MITCHELL, W. and KLINE, DG. Resection and graft repair for localized hypertrophic neuropathy. *Neurosurgery*, 1998, vol. 43, p. 78-83. PMID:9657192. <http://dx.doi.org/10.1097/00006123-199807000-00051>
- KOROMPILIA, AV., PAYATAKES, AH., BERIS, AE., VEKRIS, MD., AFENDRAS, GD. and SOUCACOS, PN. Sciatic and peroneal nerve injuries. *Microsurgery*, 2006, vol. 26, p. 288-94. PMID:16628741
- KURTOGLU, Z., AKTEKIN, M. and ULUUTKU, M. Branching pattern of the common and superficial fibular nerves in fetus. *Clinical Anatomy*, 2006, vol. 19, n. 7, p. 621-626. PMID:16302233. <http://dx.doi.org/10.1002/ca.20235>
- ØSTERGAARD, JR., SMITH, T. and STAUSBØL-GRØN, B. Intraneural perineuroma of the sciatic nerve in early childhood. *Pediatric Neurology*, 2009, vol. 41, n. 1, p. 68-70. PMID:19520281. <http://dx.doi.org/10.1016/j.pediatrneurol.2009.01.009>
- VOLKA, JD., HADZIC, A., APRIL, E. and THYS, DM. The division of the sciatic nerve in popliteal fossa: anatomical implications for popliteal nerve blockade. *Anesthesia & Analgesia*, 2001, vol. 92, n. 1, p. 215-7. PMID: 11133630. <http://dx.doi.org/10.1097/00000539-200101000-00041>
- YUEN, EC. and SO, YT. Sciatic neuropathy. *Neurologic Clinics*, 1999, vol. 17, n. 3, p. 617- 31. [http://dx.doi.org/10.1016/S0733-8619\(05\)70155-9](http://dx.doi.org/10.1016/S0733-8619(05)70155-9)

Received March 18, 2014
Accepted December 8, 2014